A Case of Radiation-induced Differentiated Thyroid Cancer

Arnauld Muhoza[1*], Esso-Mada Kpekpeou[1], Maha Chaoui[1], Aicha El Boukhrissi[1], Nadia Ismaili Alaoui[1]

[1]Nuclear Medicine Department, Hassan II University Hospital Center, Fès, Morocco

Swiss Journal of Radiology and Nuclear Medicine - SJORANM GmbH - Rosenweg 3 - CH-6340 Baar - Switzerland

Abstract

Introduction: Childhood exposure to ionizing radiation is associated with later differentiated thyroid cancer. Long-term follow-up addresses treatment response, late toxicity and subsequent malignancies.
Case report: A 16-year-old girl developed papillary thyroid carcinoma after cranial/posterior fossa radiotherapy for medulloblastoma at age five. After thyroidectomy and three courses of radioiodine therapy, thyroglobulin decreased from 110 to 5 ng/mL and pathological pulmonary iodine uptake resolved. Continued clinical, biochemical and imaging surveillance is reported.
Conclusion: This case illustrates the importance of prolonged follow-up after childhood radiotherapy and of distinguishing population-level risk estimates from an individual patient's treatment history.

Keywords: *Ionizing radiation, differentiated thyroid cancer, radioiodine therapy*

*Corresponding author: Arnauld Muhoza - received: 06.12.2025 - peer reviewed, accepted and published: 29.12.2025

Introduction

Exposure to ionizing radiation during childhood is associated with an increased risk of differentiated thyroid cancer [1-3]. Follow-up after radiotherapy addresses oncological response, late toxicity and subsequent malignancies [2]. Thyroid surveillance is particularly relevant after treatment involving the neck, upper mediastinum or craniospinal axis, or after total-body irradiation. Risk assessment considers age, field and dose rather than an absolute age cutoff [3]. We report papillary thyroid carcinoma in a 16-year-old girl with a history of medulloblastoma treated with cranial/posterior fossa irradiation at age five, managed at Hassan II-Fez University Hospital Center.

Observation

This is a 16-year-old female patient presenting with height and weight growth retardation for the past two years, with a medical history of posterior fossa medulloblastoma diagnosed and surgically treated at the age of 5 years. She underwent cranial and posterior fossa irradiation with 21 sessions totaling 55.8 Gy (end of irradiation 25th September 2013) and was subsequently declared cured under annual clinical and radiological surveillance. In 2024, she presented to the pediatric clinic with a WHO stage 3 cervical swelling of thyroid origin. Cervical palpation found a thyroid nodule associated with cervical adenopathy. Cervical ultrasound revealed a 25*23 mm nodule in the right thyroid lobe, classified EU-TIRADS 4, with suspicious adenopathy in lymph node chains IIa, III, and IV. The baseline diagnostic chest-abdomen-pelvis CT scan revealed pulmonary micronodules. Fine-needle aspiration was not performed due to the inaccessibility of the nodule. A total thyroidectomy with lymph node dissection was performed in August 2024, and the pathological examination of the thyroid specimen and

Open Access · CC BY 4.0 · © 2025 The Author(s) · Published by SJORANM GmbH, Switzerland

lymph node areas found a differentiated thyroid cancer classified as pT1bN1bM1 (Figure 1). The patient was subsequently referred to the nuclear medicine department for iratherapy. She received her first course of radioiodine therapy about 10 weeks after surgery with 50 mCi (1.85 GBq). The peri-radioiodine assessment in a withdrawal state showed: TSH 64.3 mUI/ml, thyroglobulin 110 ng/ml, negative anti-thyroglobulin antibodies. The whole-body scan indicated residual thyroid tissue with multiple pathological areas of uptake in the lungs (Figure 2), corresponding to nodules described on the initial CT. The remainder of the initial CT showed an empty thyroid bed with no cervical adenopathy. The second course of radioiodine therapy was administered with 50 mCi (1.85 GBq). The assessment on withdrawal showed: TSH 64.4 mUI/ml, thyroglobulin 40 ng/ml, anti-thyroglobulin antibodies 32.4 IU (negative). The whole-body I-131 scan showed slight residual thyroid tissue and regression of multiple pathological pulmonary uptake foci (Figure 3). The subsequent CT scan showed an empty thyroid bed with no cervical adenopathy and notable regression (>30%) of pulmonary nodules, most of which had become calcified. A third course of radioiodine therapy was administered at a dose of 100 mCi (3.7 GBq). The withdrawal assessment revealed: TSH 64.4 mUI/ml, thyroglobulin 5 ng/ml, anti-thyroglobulin antibodies 20 IU (negative). The whole-body scan showed complete resolution of pathological pulmonary uptakes (Figure 4). The CT scan showed no pathological cervical enhancement and calcified pulmonary micronodules with an interstitial syndrome. These findings document marked biochemical and scintigraphic improvement. The patient remains under annual follow-up of tumor markers and suppressive-dose L-thyroxine, targeting a high-risk TSH goal during the first five years.

Discussion

Differentiated thyroid cancer in children, whether apparently spontaneous or secondary to irradiation, is a rare entity. It is exceptional before the age of ten, and its incidence increases with age [3], [4]. During childhood, the thyroid gland remains the most sensitive organ to the carcinogenic effects of ionizing radiation for several reasons [1, 5]. External irradiation for the treatment of benign or malignant diseases during childhood increases the risk of developing thyroid tumors after a latency period of at least five years. Additional risk factors include the combination of irradiation and chemotherapy, particularly with alkylating agents at doses below 20 Gy, female sex, and younger age at cancer treatment onset. This increased risk persists throughout life and justifies continuous follow-up beyond five years [1], [2], [5].

Ionizing radiation can contribute to thyroid carcinogenesis through DNA damage and genomic instability [5]. Children are particularly susceptible, and risk depends on age at exposure and absorbed thyroid dose. Missaoui et al. report that, among thyroid tumors diagnosed after a childhood thyroid dose of 1 Gy, approximately 80% may be attributable to radiation [4]. This is an attributable fraction among tumors, not an 80% probability of developing thyroid cancer. In this patient, the reported 55.8 Gy concerned cranial/posterior fossa treatment at age five. This treatment dose must not be interpreted as the absorbed thyroid dose. The differential diagnosis includes familial syndromes such as Cowden syndrome, familial adenomatous polyposis/Gardner syndrome and Werner syndrome [3]. The reported clinical and genetic evaluation did not identify a familial predisposition.

From a histopathological standpoint, radiation-induced and apparently spontaneous thyroid cancers share up to 80% of their features, most frequently of the classical type [5]. Aggressive histologic variants, such as the solid or diffuse sclerosing types, are more closely associated with younger age at onset than with radio-induced etiology [5]. The classic papillary subtype is the predominant form of thyroid cancer in children, accounting for 85–93% of cases, with a slow progression and limited spread. It usually occurs in older children and adolescents. Our patient presented with a classical papillary thyroid carcinoma consistent with findings in the literature. More aggressive variants, often seen in younger children, tend to present with more extensive disease at diagnosis [3].

Cervical lymph node metastases are frequent at diagnosis, with an incidence exceeding 75% in some pediatric series. Our patient had a nodal status of N1b. Lymphadenopathies are often palpable (23–74% of cases depending on the series) and must be distinguished from benign adeno-

pathies. Pulmonary metastases are more common in children than in adults, occurring in up to 25% of pediatric cases versus less than 5% in adults [3]. In our patient, pulmonary metastases were detected on whole-body post-therapy scans after the first treatment (M1 status). The advanced stage at diagnosis and management may be explained by a two-year delay in consultation.

The management of radiation-induced thyroid cancers is similar to that of apparently spontaneous differentiated thyroid cancers, depending on recurrence risk according to the 2025 ATA recommendations and the TNM staging system (UICC/AJCC revised 2017) [2], [6]. Radioiodine therapy is recommended at a dose of 1 mCi/kg, with therapeutic doses ranging between 1.85 and 3.7 GBq (50–100 mCi) [7]. Our patient received two treatments at 50 mCi and a third one at 100 mCi. However, thyroid cancers in younger children are often more extensive at diagnosis [3]. Close monitoring is imperative to prevent complications associated with radiation-induced thyroid cancer [5], and lifelong follow-up is required because of the risk of very late recurrences [7].

Despite favorable progress, our patient remains under lifelong clinical, biological, and imaging surveillance, including annual tumor marker evaluations under L-Thyroxine therapy at a dose of 2.4 µg/kg, with imaging as indicated. From a prognostic perspective, radiation-induced and apparently spontaneous thyroid cancers share a similar outcome, generally favorable in well-differentiated classical forms and less favorable in aggressive or poorly differentiated variants, provided that initial treatment is appropriate and follow-up is prolonged [5], [8]. Overall survival is excellent typically above 90% at 20 years with very low mortality for both sporadic and radiation-induced forms [9].

Berrington de Gonzalez et al. followed 647,672 adult five-year cancer survivors for a mean of 12 years; 60,271 (9%) developed a second solid cancer [10]. This 9% is not a risk-reduction estimate. The adult cohort does not define individual risk after childhood treatment. Follow-up imaging should be clinically justified and unnecessary radiation exposure avoided.

Conclusion

Long-term surveillance after childhood irradiation is essential for detecting late effects and subsequent malignancies. Thyroid cancer risk is related to age and thyroid exposure. Early recognition and appropriate treatment support favorable outcomes. Follow-up should be individualized to the prior treatment and clinical findings.

Figures

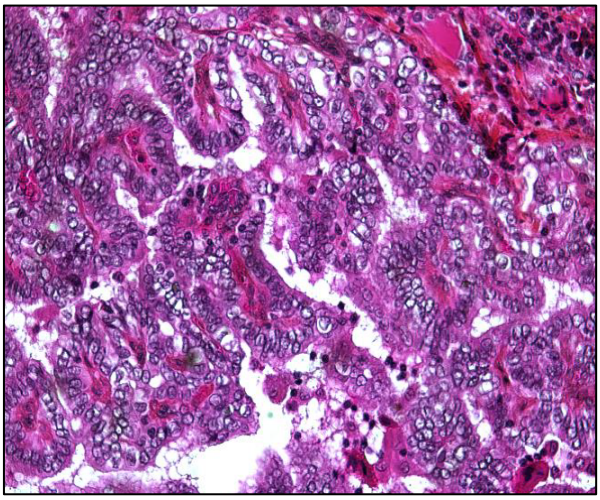

Figure 1(a): Histological examination from thyroid fragments and cervical lymph nodes revealed a tumoral proliferation arranged in papillary and vesicular structures, centered around fibrovascular cores, producing a classic ground-glass appearance

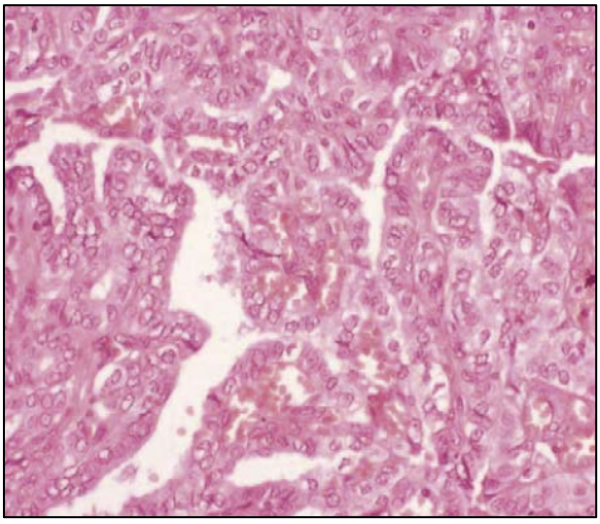

Figure 1(b): Histological examination from thyroid fragments and cervical lymph nodes revealed a tumoral proliferation arranged in papillary and vesicular structures, centered around fibrovascular cores, producing a classic ground-glass appearance



Figure 2: Post-first-treatment whole-body scan with iodine-131 demonstrated the presence of iodine-avid thyroid remnants, along with multiple sites of pathological uptake in the lungs corresponding to micro- and macronodular pulmonary lesions

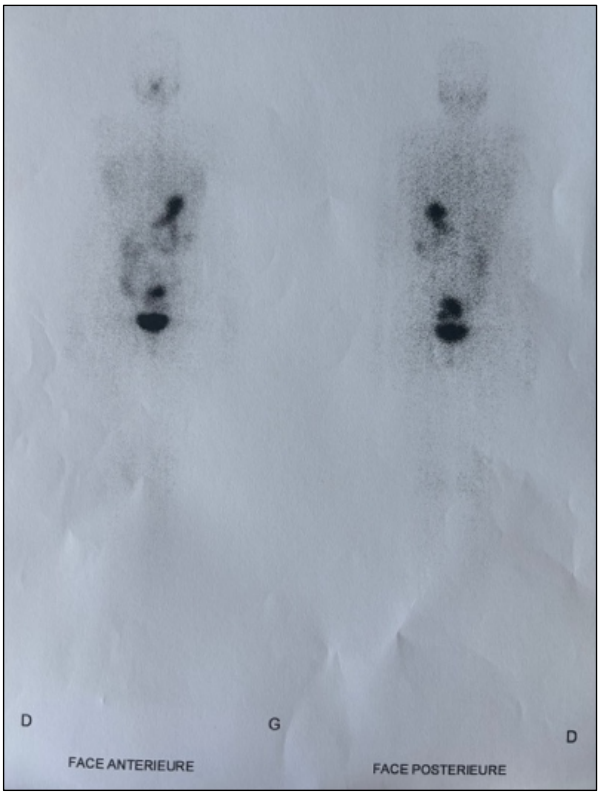

Figure 4: Post-third-treatment whole-body scan with iodine-131 showed complete resolution of the abnormal pulmonary uptake sites



Figure 3: Post-second-treatment whole-body scan with iodine-131 revealed a small thyroid remnant and marked regression of abnormal uptake in both lung fields

Correspondence to:
Arnauld Muhoza
Nuclear Medicine Department, Hassan II University Hospital Center, Fès, Morocco
Centre Hospitalier Universitaire Hassan IIFès, Morocco, Centre Hospitalier HrazemBP:1835 Atlas, Fès, Avenue Hassan IIFes 30050, Marokko

Declarations

Consent for publication: The author clarifies that written informed consent was obtained and the anonymity of the patient was ensured. This study submitted to Swiss J. Rad. Nucl. Med. has been conducted in accordance with the Declaration of Helsinki and according to requirements of all applicable local and international standards. All authors contributed to the conception and design of the manuscript, participated in drafting and

revising the content critically for important intellectual input, and approved the final version for publication. Each author agrees to be accountable for all aspects of the work, ensuring its accuracy and integrity.
Competing interests: No competing interests.
Funding: No funding was required for this study.

Conflict of interest:

The authors declare that there were no conflicts of interest within the meaning of the recommendations of the International Committee of Medical Journal Editors when the article was written.

Disclaimer/Publisher's Note:

The statements, opinions and data contained in all publications are solely those of the individual author(s) and contributor(s) and not of Swiss J. Radiol. Nucl. Med. and/or the editor(s). Swiss J. Radiol. Nucl. Med. and/or the editor(s) disclaim responsibility for any injury to people or property resulting from any ideas, methods, instructions or products referred to in the content.

License Policy:

This work is licensed under a Creative Commons Attribution 4.0 International License.
This license requires that reusers give credit to the creator. It allows reusers to distribute, remix, adapt, and build upon the material in any medium or format, even for commercial purposes.

SJORANM-LinkedIn:

Check out our journal's *LinkedIn profile* with over 11K registered followers from the Radiologic & Nuclear Medicine Imaging field.

References

1. Ech-Charraq I, Ben Rais N. Le cancer de la thyroïde chez l'enfant (à propos de 9 cas). Médecine Nucléaire. 2009 Dec;33(12):737–40. https://doi.org/10.1016/j.mednuc.2009.05.007

2. Lugat A, D. Drui, S. Baron, E. Thebaud, S. Supiot , E. Jouglar, M. Doré.Effets secondaires endocriniens de la radiothérapie: diagnostic, prévention et traitements. Cancer/Radiothérapie. 2022 Nov;26(8):1078–89. https://doi.org/10.1016/j.canrad.2021.12.008

3. Leboulleux S, Hartl D, Baudin É, Schlumberger M. Cancer differencié de la thyroïde de l'enfant. Bulletin du Cancer. 2012 Nov;99(11):1093–9. https://doi.org/10.1684/bdc.2012.1645

4. Missaoui B, Yeddes I, Meddeb I, Bennour S, Ben Ghachem T, Mhiri A. Particularité du cancer différencié de la thyroïde dans les suites d'une irradiation cervicale : à propos d'un cas. Annales d'Endocrinologie. 2018 Sept;79(4):386. https://doi.org/10.1016/j.ando.2018.06.605

5. Schlumberger M, S. Chevillard, K. Ory, C. Dupuy, B. Le Guen, F. de Vathaire. Cancer de la thyroïde après exposition aux rayonnements ionisants. Cancer/Radiothérapie. 2011 Aug;15(5):394–9. https://doi.org/10.1016/j.canrad.2011.05.002

6. Ringel Matthew D, Julie Ann Sosa, Zubair Baloch, Lindsay Bischoff, Gary Bloom, Gregory A. Brent, Pamela L. Brock, Roger Chou, Robert R. Flavell, Whitney Goldner, Elizabeth G. Grubbs, Megan Haymart, Steven M. Larson, Angela M. Leung, Joseph Osborne, John A. Ridge, Bruce Robinson, David L. Steward, Ralph P. Tufano, and Lori J. Wirth.2025 American Thyroid Association Management Guidelines for Adult Patients with Differentiated Thyroid Cancer. Thyroid®. 2025 Aug 1;35(8):841–985. https://doi.org/10.1177/10507256251363120

7. Mhiri A, Jemai Ghezaiel M, Elbez I, Slim I, Yeddes I, Meddeb I, Ben Slimène MF. Le cancer différencié de la thyroïde chez les patients de moins de 20 ans : à propos de 20 cas. Médecine Nucléaire. 2013 Oct;37(10–11):416–419. https://doi.org/10.1016/j.mednuc.2013.09.029

8. Cosset J.-M., C. Chargari, C. Demoor , P. Giraud, S. Helfre , F. Mornex , A. Mazal . Prévention des cancers radio-induits. Cancer/Radiothérapie. 2016 Sept;20:S61–8. https://doi.org/10.1016/j.canrad.2016.07.030

9. Leenhardt L, F. Ménégaux, B. Franc, C. Hoang, S. Salem, M.-O. Bernier, L. Dupasquier-Fédiaevsky, E. Le Marois, A. Rouxela, J.-P. Chigot, L. Chérié-Challine, A. Aurengo. Cancers de la thyroïde. EMC - Endocrinologie. 2005 Feb;2(1):1–38. https://doi.org/10.1016/j.emcend.2004.10.003

10. Berrington de Gonzalez A, Curtis RE, Kry SF, et al. Proportion of second cancers attributable to radiotherapy treatment in adults: a cohort study in the US SEER cancer registries. Lancet Oncol. 2011;12(4):353-360. doi: https://doi.org/10.1016/S1470-2045(11)70061-4