Ectopic Thyroid In The Anterior Mediastinum Coexisting With A Normally Positioned Thyroid Gland In Neck: Case Report

Arshed Hussain Parry MD*[1], Zahia Shabir MBBS[1], Pirzada Mohammad Suhaib MD[1], Irfan Yousuf Wani DM[2], Mir Wajahat Un Nazir, MD[3], Shabir Ahmad Bhat, MD[1]

[1]Department of Radiodiagnosis, Government Medical College, Srinagar, Jammu & Kashmir, India

[2]Department of General Medicine, Government Medical College, Srinagar, Jammu & Kashmir, India

[3]Department of Pathology, Government Medical College, Srinagar, Jammu & Kashmir, India

Swiss Journal of Radiology and Nuclear Medicine - SJORANM GmbH - Rosenweg 3 - CH-6340 Baar - Switzerland

Abstract

Introduction: *Ectopic thyroid gland is a developmental anomaly resulting from abnormal migration of thyroid tissue from its embryologic origin at the base of the tongue to its normal location in the neck. The coexistence of normally located thyroid tissue with an ectopic thyroid in the anterior mediastinum is an exceptionally rare finding. Most patients with ectopic thyroid tissue are asymptomatic; however, when the ectopic tissue enlarges, it may produce compressive symptoms, including tracheal or esophageal compression.*
Case presentation: *We report the case of a 50-year-old woman who presented with an insidious onset of dry cough for one year which was unresponsive to conventional treatment. Imaging revealed a superior mediastinal mass along with a normally positioned thyroid gland in the neck. Initially based on imaging a provisional diagnosis of germ cell tumor vs lymphoma was made. An ultrasound guided biopsy through sternal notch was performed with histopathological examination confirming benign, enlarged thyroid tissue without evidence of malignancy.*
Conclusion: *This case underscores the importance of considering ectopic thyroid tissue within the anterior mediastinum in the differential diagnosis of anterior mediastinal masses, which more commonly include thymic tumors, germ cell tumors, and lymphomas.*

Keywords: *Ectopic thyroid; anterior mediastinal mass; mediastinal thyroid.*

*Corresponding author: Arshed Hussain Parry - received: 01.10.2025 - peer reviewed, accepted and published: 30.11.2025

Introduction

Ectopic thyroid is a rare but well known condition in which thyroid tissue is located at a site other than its normal anatomical location within the neck. It can be present anywhere along its path of descent from foramen cecum to anterior lower neck which may occur as a result of abnormalities in development or migration from primitive foregut to pre-tracheal region. Rarely, thyroid tissue may be found beyond this path or away from midline within the trachea, mediastinum, heart, or even the abdomen (1, 2). The presence of an ectopic thyroid with a normally located thyroid gland in neck is extremely rare (3, 4).

Although the incidence varies among the cases reported in literature, the most common type is the lingual thyroid located at the base of the tongue (3). Mediastinal thyroid accounts for less than 1% of ectopic thyroid and often coexists with a normal orthotopic thyroid tissue (5, 6).
The condition is mostly asymptomatic and is often diagnosed incidentally when a person is evaluated for some unrelated condition. Not infrequently, it may give rise to symptoms based on its location secondary to mass effect, or symptoms related to hypothyroidism and rarely, hyperthyroidism.
We report a case of a female patient with an ectopic thyroid coexisting with a normally located thyroid where the diagnosis was established on histopathology.

Case presentation

A 50-year old female patient, with otherwise no comorbidity, was referred to us for evaluation of chronic cough that she was experiencing on and

Open Access · CC BY 4.0 · © 2025 The Author(s) · Published by SJORANM GmbH, Switzerland

off from past one year. The cough was non-productive and mild initially. She had sought medical consultation couple of times but was never evaluated for the same. A respiratory, cardiovascular and ENT examination was done by the treating physician which was unremarkable. Because of persistence of symptoms, a chest X-ray was ordered that revealed an abnormal widening of superior mediastinum with sharply demarcated margins (Fig. 1). The right and left para-tracheal stripes were significantly widened. No other abnormality was found.

Baseline lab investigations were undertaken that revealed normal blood count, and renal and liver function tests. Serum C-reactive protein and ESR were within normal limits. Thyroid function test revealed a TSH level of 1.4mIU/L.

A contrast enhanced CT scan of neck and chest was ordered which revealed a well-defined 6.8x 4.6 cm rounded mass within the superior mediastinum with heterogeneous enhancement pattern. The mass was separate from the thyroid gland. No definite communication was found between the mass and orthotropic thyroid (Fig. 2).

Further evaluation on ultrasound using a high frequency linear transducer showed a well circumscribed fairly homogenous mass lesion in retrosternal location with vascularity upon Doppler analysis (Fig. 3). Thyroid gland was seen at its normal location.
A preliminary radiological diagnosis of germ cell tumor vs. lymphoma was made and patient was advised biopsy of the lesion. An ultrasound guided biopsy of the lesion was performed using 18G biopsy gun with coaxial assembly. Histopathological analysis revealed normal thyroid follicles filled with colloid with maintained basal polarity of nuclei (H&E stain) (Fig. 4, 5). No signs of malignancy were seen.

Discussion

Ectopic thyroid tissue can be present anywhere along its path of descent from the floor of tongue to pre-tracheal location in lower neck. Rarely, it may be seen beyond this course anywhere from neck up to abdominal cavity or away from midline within salivary glands. It is not uncommon to find an ectopic thyroid tissue with a normally positioned orthotopic thyroid gland. Increase in size in times of physiological stress which may or may not be associated with hyper-or hypothyroidism may lead to mass effect producing symptoms based on its location. Mediastinal thyroid with a normal thyroid in neck is exceedingly rare and patients may present with cough, stridor, dyspnea, dysphagia or signs of thyroid dysfunction. Careful analysis of history and physical examination along with basic laboratory investigations are important. Ultrasound helps in confirming the diagnosis of normal neck thyroid. It also aids in detection of retrosternal extension of thyroid from a purely mediastinal ectopic thyroid. Ultrasound is also useful in guiding biopsy if the mass is visible through suprasternal notch.
Contrast enhanced CT aids in establishing attenuation and contrast characteristics of normal and ectopic thyroid. MRI is another excellent modality to assess similarities between normal and ectopic thyroid. Scintigraphy is also very helpful in localizing ectopic thyroid, however, can be negative in cases of necrosis or malignant transformation (7). Despite all these radiological modalities, the definitive diagnosis is often established only after histopathological analysis of biopsied tissue. Despite most patients being euthyroid, surgical intervention in case of ectopic thyroid may be required especially when symptoms of airway compression exist and rarely in cases of malignant transformation (8).

Conclusion

Mediastinal ectopic thyroid is a rare form among the various ectopic locations of thyroid especially when a normal orthotopic gland coexists. This case underscores the importance of considering ectopic thyroid tissue within the anterior mediastinum in the differential diagnosis of anterior mediastinal masses, which more commonly include thymic tumors, germ cell tumors, and lymphomas. Our aim was to highlight the fact that despite advancement in the radiological methods, definitive diagnosis may still depend on the analysis of cellular structure and any mediastinal mass should always point towards the possibility of the mass being ectopic thyroid tissue.

Correspondence to:
Arshed Hussain Parry, M.D
Department of Radiodiagnosis, Government Medical College, Srinagar, Jammu & Kashmir, India

DEPARTMENT OF RADIO DIAGNOSIS AND IMAGING

Declarations

Consent for publication: The author clarifies that written informed consent was obtained and the anonymity of the patient was ensured. This study submitted to Swiss J. Rad. Nucl. Med. has been

conducted in accordance with the Declaration of Helsinki and according to requirements of all applicable local and international standards. All authors contributed to the conception and design of the manuscript, participated in drafting and revising the content critically for important intellectual input, and approved the final version for publication. Each author agrees to be accountable for all aspects of the work, ensuring its accuracy and integrity.
Competing interests: No competing interests.
Ethics approval and consent to participate:
Patient gave written informed consent to use their data in case write-up. No ethics approval is needed from the Government Medical College, Srinagar, for a case write-up. Consent for publication: Written informed consent was obtained from the patient for publication of this case report and accompanying images.

Funding: No funding was required for this study.

Conflict of interest:

The authors declare that there were no conflicts of interest within the meaning of the recommendations of the International Committee of Medical Journal Editors when the article was written.

Disclaimer/Publisher's Note:

The statements, opinions and data contained in all publications are solely those of the individual author(s) and contributor(s) and not of Swiss J. Radiol. Nucl. Med. and/or the editor(s). Swiss J. Radiol. Nucl. Med. and/or the editor(s) disclaim responsibility for any injury to people or property resulting from any ideas, methods, instructions or products referred to in the content.

License Policy:

This work is licensed under a Creative Commons Attribution 4.0 International License. This license requires that reusers give credit to the creator. It allows reusers to distribute, remix, adapt, and build upon the material in any medium or format, even for commercial purposes.

SJORANM-LinkedIn:

Check out our journal's *LinkedIn profile* with over 10K registered followers from the Radiologic & Nuclear Medicine Imaging field.

References

1. Guimarães MJ, Valente CM, Santos L, Baganha MF. Ectopic thyroid in the anterior mediastinum. Jornal Brasileiro de Pneumologia. 2009;35:383-7. https://doi.org/10.1590/s1806-37132009000400013
2. Kola E, Gjata A, Kola I, Guy A, Musa J, Biba V, Filaj V, Horjeti E, Nakuci D, Cobo A, Saliaj K. Ectopic thyroid tissue in the anterior mediastinum along with a normally located gland. Radiology Case Reports. 2021 Nov 1;16(11):3191-5. https://doi.org/10.1016/j.radcr.2021.07.064
3. Elashmawy A, Achkar A, Federico A, Hilu J. Ectopic Thyroid Tissue in the Anterior Mediastinum: A Case Report. Cureus. 2024 Jun 27;16(6). https://doi.org/10.7759/cureus.63293
4. Regal M, Kamel MM, Alyami H, Al-Osail EM. Mediastinal ectopic thyroid mass with normal thyroid function and location: case report. International Journal of Surgery Case Reports. 2018 Jan 1;52:5-7. https://doi.org/10.1016/j.ijscr.2018.09.033
5. Aal MA, Scheer F, Andresen R. Ectopic mediastinal thyroid tissue with a normally located thyroid gland. Iranian Journal of Radiology. 2015 Jan 1;12(1):e7054. https://doi.org/10.5812/iranjradiol.7054
6. Kolwalkar J, Samant D, Borkar S, Vidyasagar MS, Vaggar JN. Ectopic colloid goiter in mediastinum with normal thyroid gland. Journal of Cardiothoracic Surgery. 2024 Feb 20;19(1):103. https://doi.org/10.1186/s13019-024-02574-5
7. Muzurović E, Smolović B, Miladinović M, Muhović D, Čampar B. Diagnosis and treatment of mediastinal ectopic thyroid tissue with normally located thyroid gland and primary hyperparathyroidism: a case report. Gland surgery. 2021 Apr;10(4):1532. https://doi.org/10.21037/gs-20-626
8. Metere A, De Giacomo T, Vergine M, Biffoni M, Giacomelli L. Diagnosis and management of a mediastinal ectopic thyroid laying on the right bronchus: case report and review of literature. BMC surgery. 2018 Apr 4;18(1):19. https://doi.org/10.1186/s12893-018-0354-y

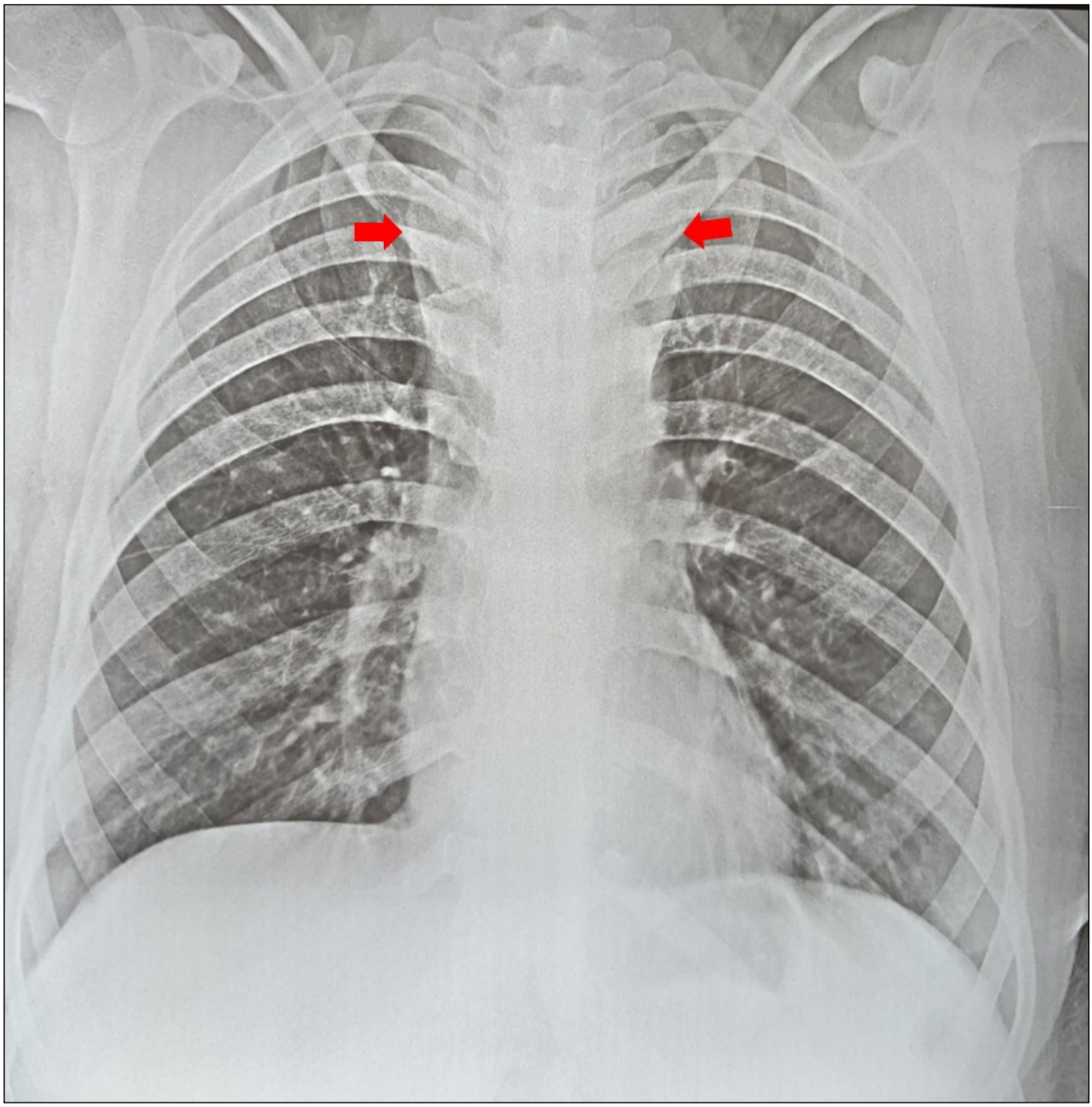

Figure 1: The posteroanterior (PA) chest radiograph demonstrates widening of the superior mediastinum, as indicated by the red arrows.

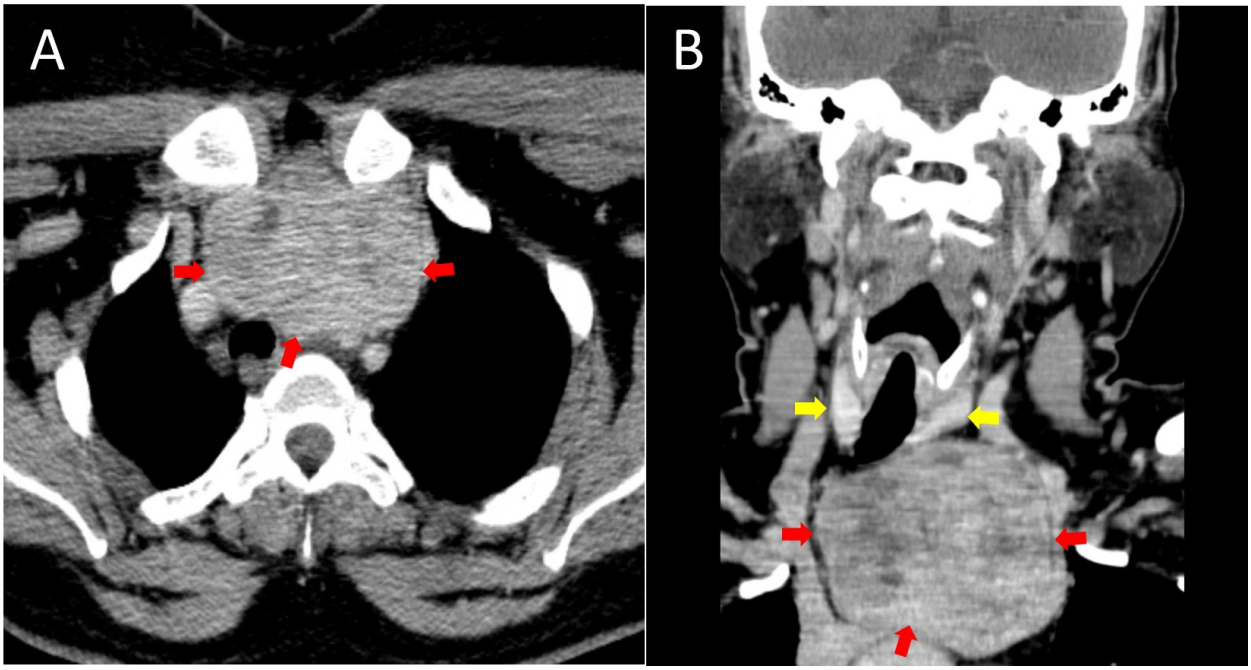

Figure 2: The contrast-enhanced CT scan, shown in both axial (A) and coronal planes (B), reveals a well-circumscribed anterior mediastinal mass with heterogeneous enhancement, indicated by the red arrows. In image B, the normal thyroid gland is visualized in the neck, highlighted by the yellow arrows

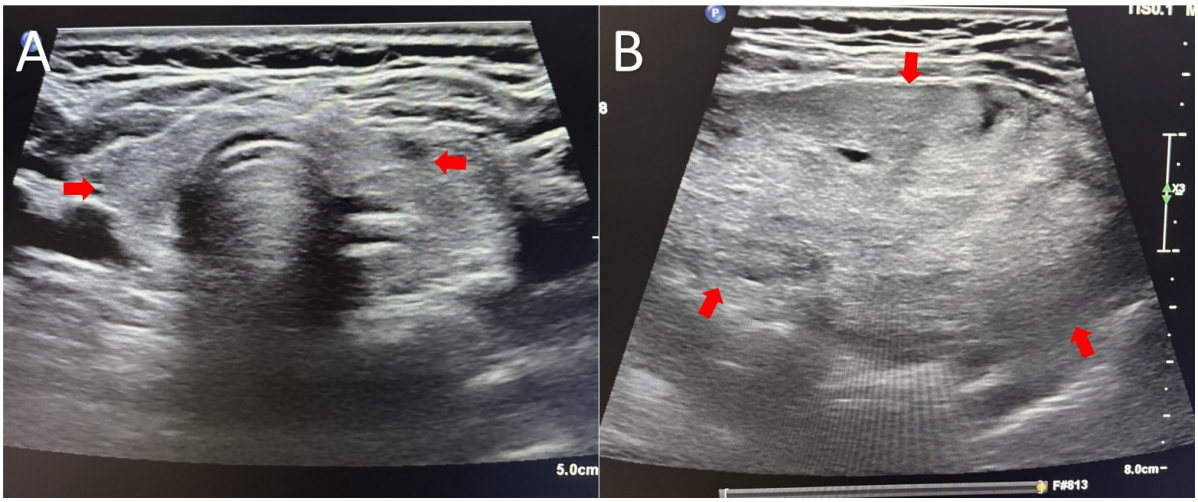

Figure 3: High-resolution ultrasound images show a normal thyroid gland in the neck (image A), indicated by the red arrows. Ultrasound obtained through the suprasternal notch (image B) demonstrates a homogeneous, isoechoic mass within the superior mediastinum (red arrows in B).

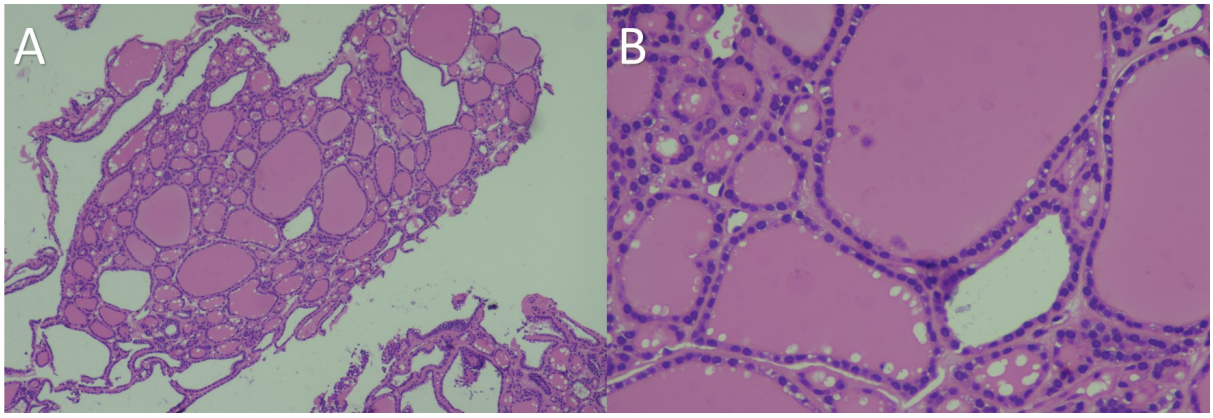

Figure 4: Low power (10x) photomicrograph showing benign thyroid follicles (H and E stain) (A). High power (40x) photomicrograph showing normal thyroid follicles filled with colloid and maintained basal polarity of nuclei (H and E stain) (B)

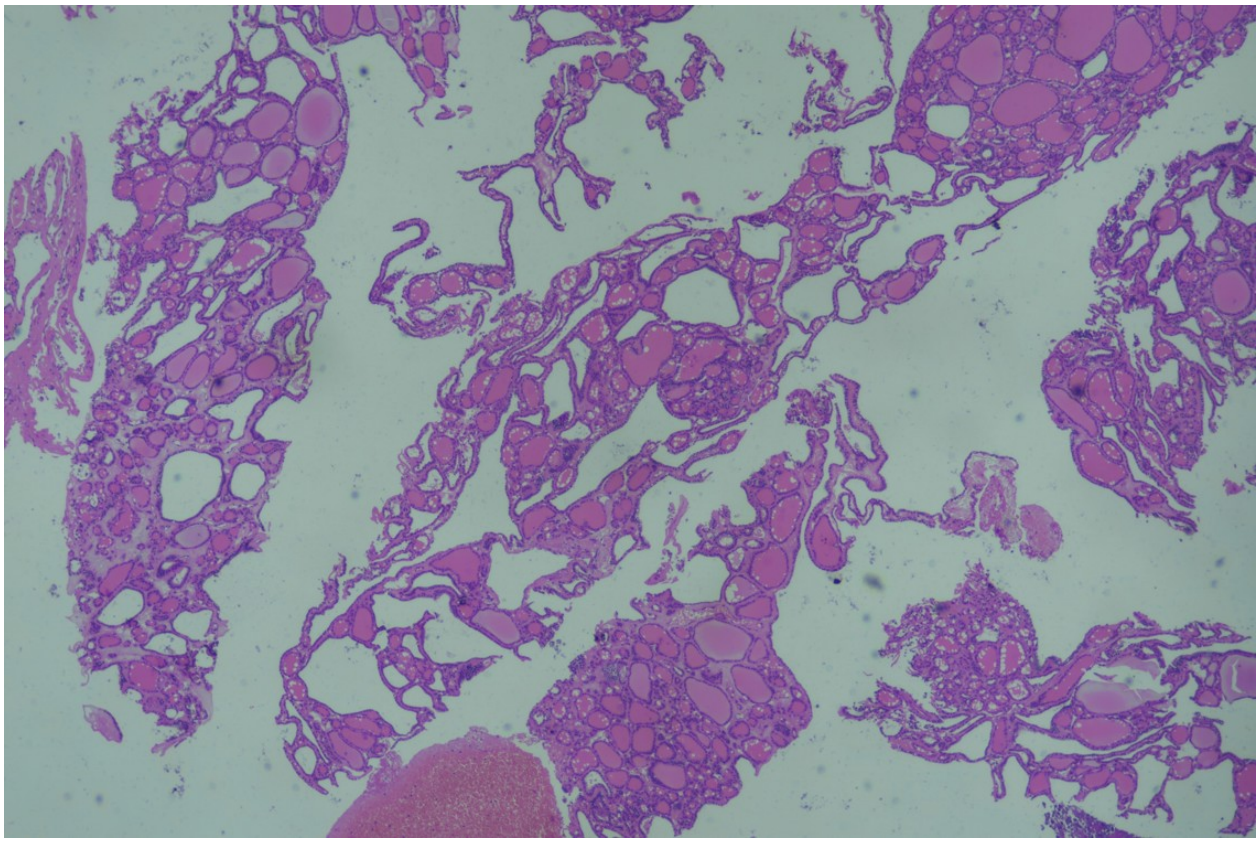

Figure 5: Scanner view (4x) photomicrograph showing normal thyroid follicles (H and E stain).