Head and Neck Lymphatic Malformations CT & MR Imaging. A brief Review

Ilson Sepúlveda[1], Arístides A. Capizzano[2], Francisco Rivas-Rodriguez[2], Allison Baez[3],

[1]Radiology Department, Otorhinolaryngology-Head & Neck Surgery and Maxillofacial Services, General Hospital of Concepcion, Concepcion, Chile. Center for Studies and Innovation in Dentistry, School of Dentistry, Finis Terrae University, Santiago, Chile
[2]Radiology Department, Division of Neuroradiology, University of Michigan Health System, Ann Arbor, Michigan, USA
[3]Otorhinolaryngology-Head & Neck Surgery Service, General Hospital of Concepcion, University of Concepción School of Medicine, Chile

Swiss Journal of Radiology and Nuclear Medicine - SJORANM GmbH - Rosenweg 3 - CH-6340 Baar - Switzerland

Abstract

Vascular anomalies correspond to a group of lesions related to disorders of vascular development, which to date remain a diagnostic and therapeutic challenge for treating physicians. Lymphatic malformations (LM) are congenital malformations that manifest as benign hamartomatous tumors of the lymphatic vessels with a marked predilection for the head, neck and oral cavity. In general terms, LM are classified as macrocystic, microcystic or a combination of both depending on the size of the lesion, which can lead to anatomical alterations and even functional deficits. The aim of this article is to provide a brief and accurate review of head and neck lymphatic malformations considering their clinical aspects, imaging tools and treatment options.

Keywords: *Lymphatic malformations, Head and Neck, Computed Tomography (CT), Magnetic Resonance (MRI), Surgery, Sclerotherapy*

[1]Corresponding author: Ilson Sepulveda Aguilar - received: 02.11.2024 - published: 30.11.2024

Introduction

Lymphatic malformations (LM) are rare slow-flow benign tumors, both congenital and acquired, that result from alterations in the complex lymphatic vessels, due to an aberrant development of the lymphatic channels resulting in an abnormal dilatation of these, which in turn, can give rise to micro cystic (cysts <2 cm in size), macro cystic (>2 cm) or mixed lesions, of isolated or multifocal presentation, with a great variety of clinical presentations in terms of location and size, since they can grow along with the anatomical site involved (1,3,18,31,37).
They usually occur in infancy, there is no gender preference, may be in the trunk, extremities and in the intrathoracic and intra-abdominal compartments, but most frequently are the neck and axilla, with 50-70% of all locations, in the majority of cases are located in the posterior triangle (54%); the remaining 25% of all LM are located in the trunk and extremities, and only 5% in parenchymal organs. Specifically in the head and neck, if we take the mylohyoid muscle as a reference, the macrocystic type is usually located inferiorly, while the microcystic variety is located superiorly (2,8,23,27,29,30,38).

Approximately 50-60% of cases are diagnosed at birth (and even earlier through the use of prenatal ultrasonography), while 80-90% have already been diagnosed by the second year of life. The incidence of LMs is estimated at 5-6% of all types of benign soft tissue tumours in children. In addition, they have been seen in association with syndromic congenital malformations such as Turner syndrome, Noonan syndrome, and chromosomal aneuploidies, describing that even these malformations could be secondary to an autosomal recessive disorder in itself. In general, this finding in adults is rare, and is usually

Open Access · CC BY 4.0 · © 2024 The Author(s) · Published by SJORANM GmbH, Switzerland

secondary to infections, trauma, neoplasms or iatrogenic lesions (1,3,4,8,16,20).
Despite the studies performed, their specific cause has not yet been determined, and there is no consensus on their treatment. As for their origin, apparently these lesions arise from sequestration of the lymphatic channels, and inappropriate communication between lymphatic vessels that have an altered drainage pattern, leading to the gradual accumulation of fluid, which gives way to a mass of soft tissue with lymphatic vessels, progressive cystic dilatation, which according to its size produces a mass effect on adjacent structures. They have also been described as ectopic or "sequestered" lymphatic tissue, which in case of local infections or trauma can grow, suggesting the existence of a connection between these and normal lymphatic tissue (2,15,17,23).

So far, there is limited evidence to suggest a hereditary component versus sporadic occurrence of LM. Among the possible causes, somatic mutations have been proposed; based on the fact that in 94% of the cases, mutations have been found in PIK3CA which codes for a catalytic subunit of the PI3K enzyme, although it is not known if these mutations alone can give rise to LM (2,5,9,19,20,21).

The International Society for the Study of Vascular Anomalies, classifies LM within vascular anomalies as microcystic, macrocystic or a mixture of both types. This classification stems from the success rates of treatment with sclerotherapy. In general, macrocystic lesions are larger than 2 cm in size, with fluid content under normal or slightly discolored skin. They generally respond well to both surgical management and sclerotherapy. Microcystic ones, on the other hand, have a size smaller than 2 cm and are usually composed of microlymphatic channels that infiltrate the surrounding soft tissue, superficially and deeply, even compromising muscle and bone, and the response to surgery and sclerotherapy is more limited, often requiring multimodal management (6,9,11,15,16,17,19,22). The de Serres classification is oriented towards LM involving the Head and Neck region, characterizing them if their involvement is uni or bilateral and supra or infrahyoid. In this way, it evaluates the degree of extension, having worse prognosis those that are bilateral and supra and infrahyoid (2,7,16,17,37).
Regarding its clinical presentation, the most frequent is a mass with painless and asymptomatic progressive and slow growth, being many times this the only finding. When the size is considerable it can generate obstructive symptoms due to mass effect, compromising vital structures depending on its location, especially in the head and neck, lost of vision, risk of airway obstruction, macroglosia, alteration in oral intake and swallowing, pain and aesthetic defect reaching a significant disfigurement. (Fig.1) (1,3,9,18,21,24,40). However, it should be taken into consideration that within the possibilities there are other lesions that could present in a similar way, such as gill cysts, abscesses, thyroglossal duct cysts, teratomas, among others. Given the variety of differential diagnoses when faced with a soft tissue lesion in the head and neck, the diagnosis is based on clinical history, physical examination and imaging study methods that play a fundamental role in its characterization, high-lighting ultrasound, magnetic resonance imaging and computed tomography (CT) (3,8,18,40).

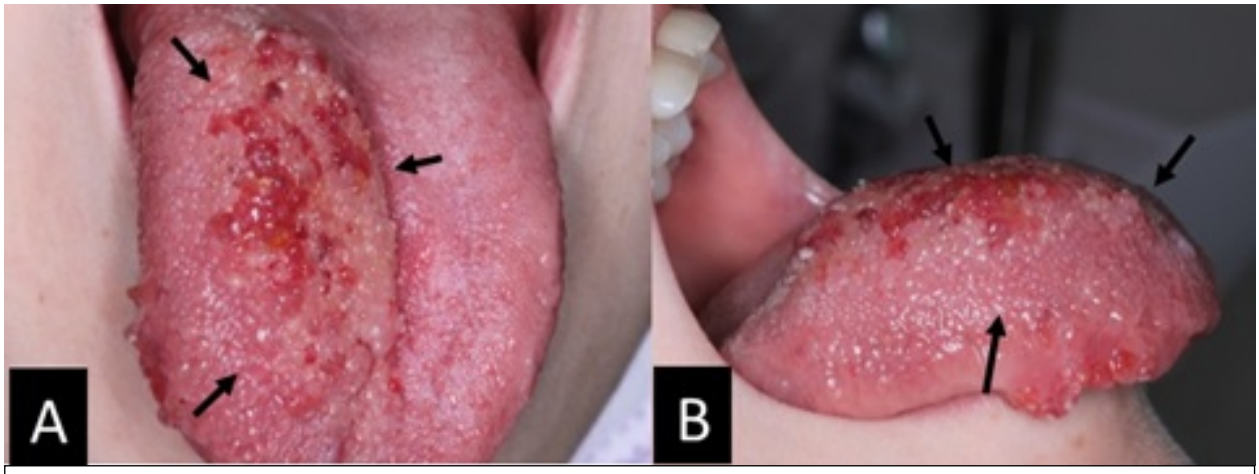

Fig 1: clinical presentation of tongue LM: swelling and colour change in the right side (black arrow). A, frontal view; B, lateral view. Courtesy of Patricio Rubio, DDS. General Hospital of Concepción, Chile.

Imaging

Doppler ultrasound is very useful as an initial screening tool, allowing to determine the charac-

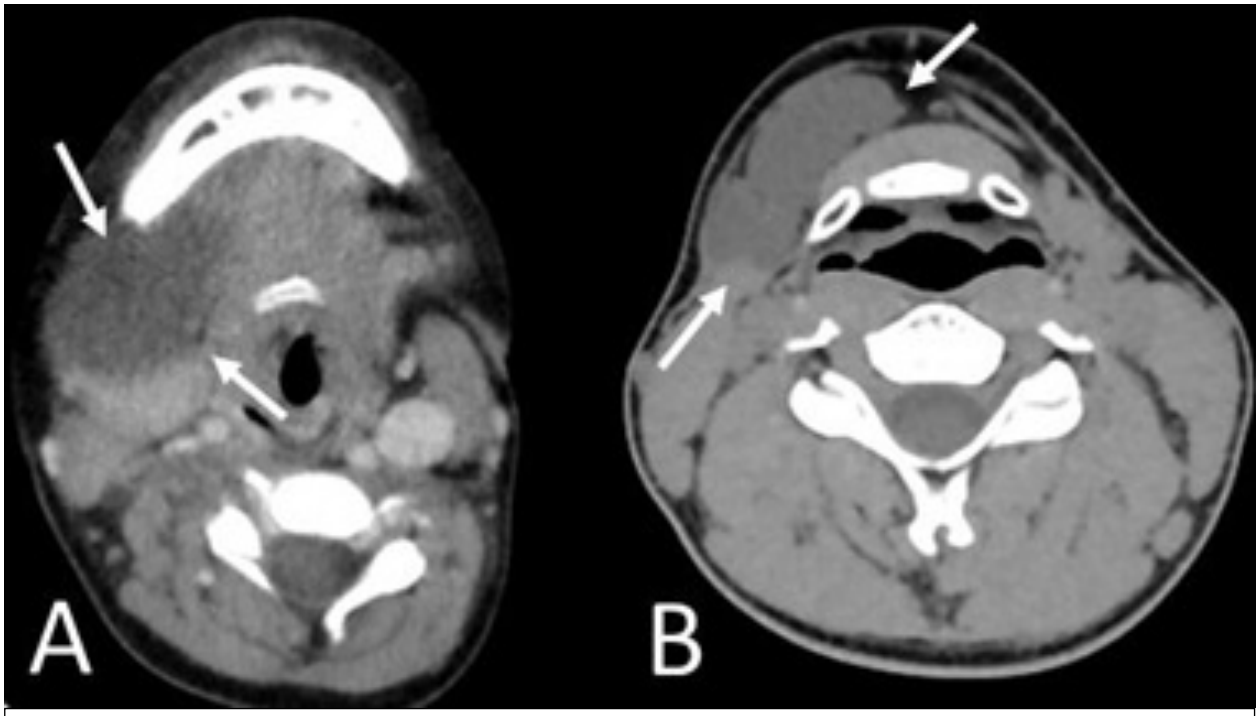

Fig 2: CT Neck. A: LM of the right submandibular space, hypodense and unilocular lesion with mass effect on the submandibular gland. B: Suprahyoid LM, multilocular under the right platysma muscle (white arrows).

teristics of the fluid and the size of the lesions that can vary from millimeters to several centimeters. It is described that these can be anechogenic or hypoechogenic, with echogenic fluid levels or liquid-liquid in cases of recent hemorrhage. It has the advantage of its low cost, its speed, noninvasive delivery of a real-time image, without requiring sedation or anesthesia or ionizing radiation. As a disadvantage, this test is operator-dependent, and highlights the poor spatial resolution and that it does not allow to evaluate its involvement in depth in a detailed way (1,2,3,8,9,11).

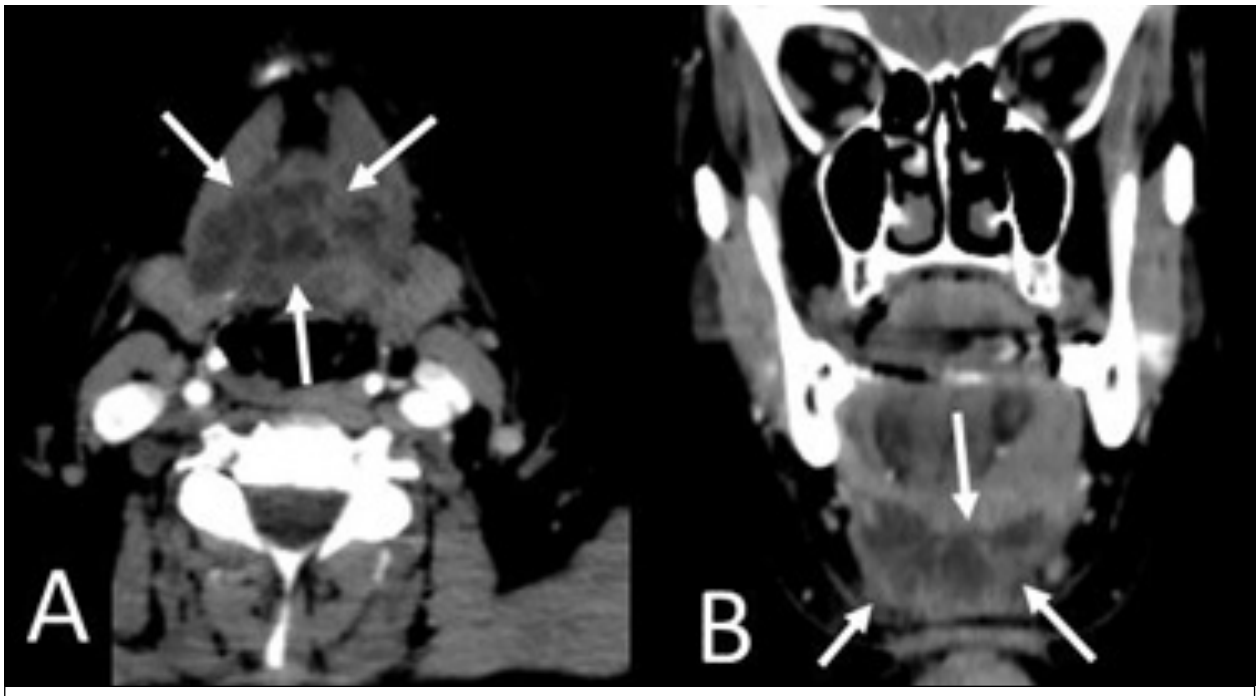

Fig 3: CT Neck. Macrocystic and multilocular suprahyoid LM, below mylohyoid muscle, with peripheral and septal enhancement after intravenous contrast injection (white arrows). A, axial view; B, coronal view.

As for the CT study, well circumscribed lesions are described with variable attenuation values, uni/multiloculated and homogeneous density. Mild septal and capsular enhancement is com-

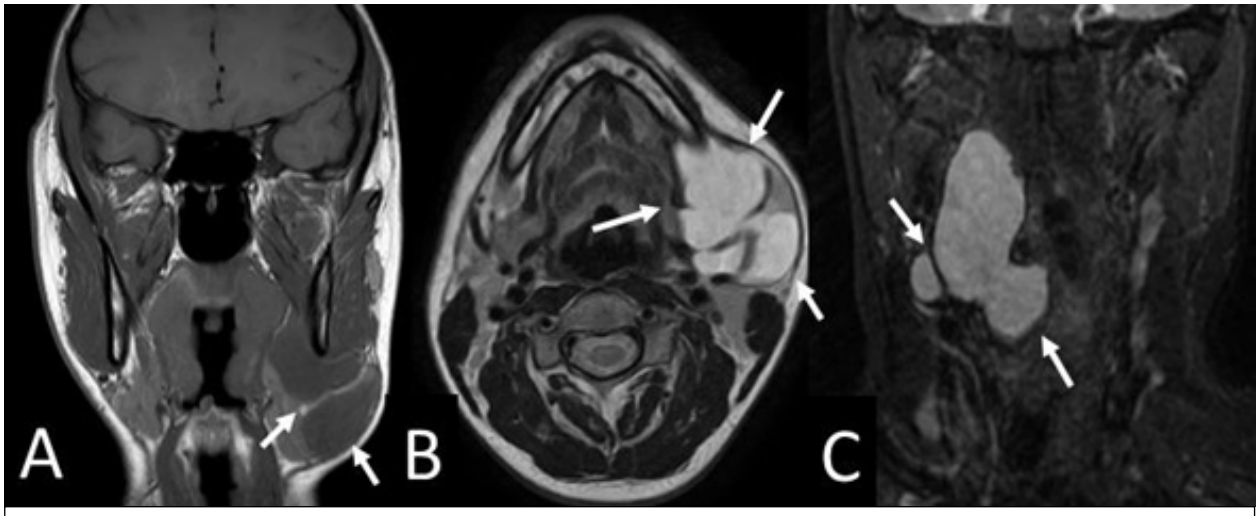

Fig 4: MRI Head: Macrocystic LM. A, coronal T1WI, isointense left submandibular space LM, with internal septa, surrounding the mandibular body and medially displacing the submandibular gland (white arrows). B, axial T2WI, hyperintense signal intensity and lateral displacement of the platysma muscle (white arrows). C, coronal STIR WI showing hyperintense signal intensity and internal septa of the right parapharyngeal space LM (with arrows).

mon after contrast administration. In cases of intralesional haemorrhage, the content has a hyperdense appearance. In addition, these masses may show calcifications and fluid level, as well as include cystic components mixed with other types of tissue. As it is known, the use of ionizing radiation is a disadvantage, especially considering that these lesions are characteristic of the pediatric population (Figs. 2,3) (3,10,15,32, 33,35).

MRI, considered as the gold standard imaging technique for determining the depth and extent of lesions, allows an excellent evaluation of soft tissues with high resolution and their relationship with the surrounding structures, relevant in LM due to its deep involvement, not only useful in diagnosis, but also for treatment planning and subsequent follow-up. MRI studies performed in late pregnancy, in congenital cervical LM, MRI can demonstrate possible extension into the mediastinum, assess proximity to the brachial plexus or obstructive airway involvement. Thin-walled, well-defined, irregularly shaped, infiltrative and generally multiloculated lesions are visualised. In T1 sequence, LM are hypo- or isointense, while in T2 they are hyperintense, and with fluid levels, due to the tendency to haemorrhage, is one of the keys to an accurate diagnosis (Fig.4).

After intravenous contrast injection, enhancement is generally observed at the level of the cyst walls and their septa, but not in the internal fluid. Only if associated with venous malformations, LMs may demonstrate diffuse enhancement. MRI is a non-invasive study, which provides three-dimensional orientation without exposing the patient to ionizing radiation. It must be taken into consideration that as a disadvantage it requires a long time to take the images, it may present artefacts due to movement and does not allow an exact detail at microvascular level, so sedation or anesthesia is often necessary (Fig.5) (2,3,9,11,28, 31,34,35,36).

Among the advantages offered by MRI, there are studies such as that of Leacy R. et al. that propose a radiological follow-up by a grading system of response to surgical resection or sclerotherapy in LM by MRI, categorizing the responses to treatment in 7 different grades with good consistency and concordance, thus aiming to standardize the results in the follow-up and response to treatment (12).

Treatment

Regarding management, to date there is still no consensus or clinical guidelines for the treatment of LM. These guidelines describe observation, medical management with the use of sclerosing agents, radiofrequency ablation, CO2 laser, among others, and surgical management, as well as a combination of both. Since it is described that 15% of the lesions may return spontaneously, it is sometimes decided to observe and follow the evolution for 18 months to 2 years, taking into account that they may have an acute growth secondary to infection or hemorrhage. In general, management is usually complex and challenging, given that as previously mentioned, the etiology is uncertain, many times the borders are poorly defined in microcystic lesions, they can be infiltrative and in contact with vital structures, in the case of ultrasound the depth and spatial resolution is low, there can be interference in the

Fig 5: MRI Head: Macrocystic right supraclavicular LM. A, coronal T1WI multilocular isointense lesion with mass effect upon ipsilateral neck muscles (white arrows). B, axial Stir WI showing fluid-fluid levels (black arrows). C, D axial and coronal T1WI+FS+GD demonstrate peripheral and septa enhancement of the lesion (white arrows)

images, there can be undiagnosed malformations of lymphatic micro vessels and there are no specific molecular markers (1,3,15,20,22,37,39).

When complete resection is achieved, the recurrence rates oscillate between 0-27% of the cases, however in case of a partial resection, situation that occurs many times due to the infiltrative nature of these lesions or when the surgery can cause a great deformation or functional alteration as in the floor of the oral cavity, the base of the tongue or retropharynx, the recurrence increases from 50 to 100% of the cases, the majority within the first year, but cases have been seen up to 10 years later (2,3,12, 13,15,18).

Among the most common complications are seromas, neurovascular damage to structures such as cranial nerves (frequently transitory), chylous fistula, chylothorax, hemorrhage, according to localization Horner and Frey syndrome, and to a lesser extent life-threatening situations such as mediastinitis and sepsis (3,13,14,21).

In addition to surgical management, the most widely used treatment to date is sclerotherapy, especially in macrocystic lesions, since the injection of the intralesional sclerosing agent

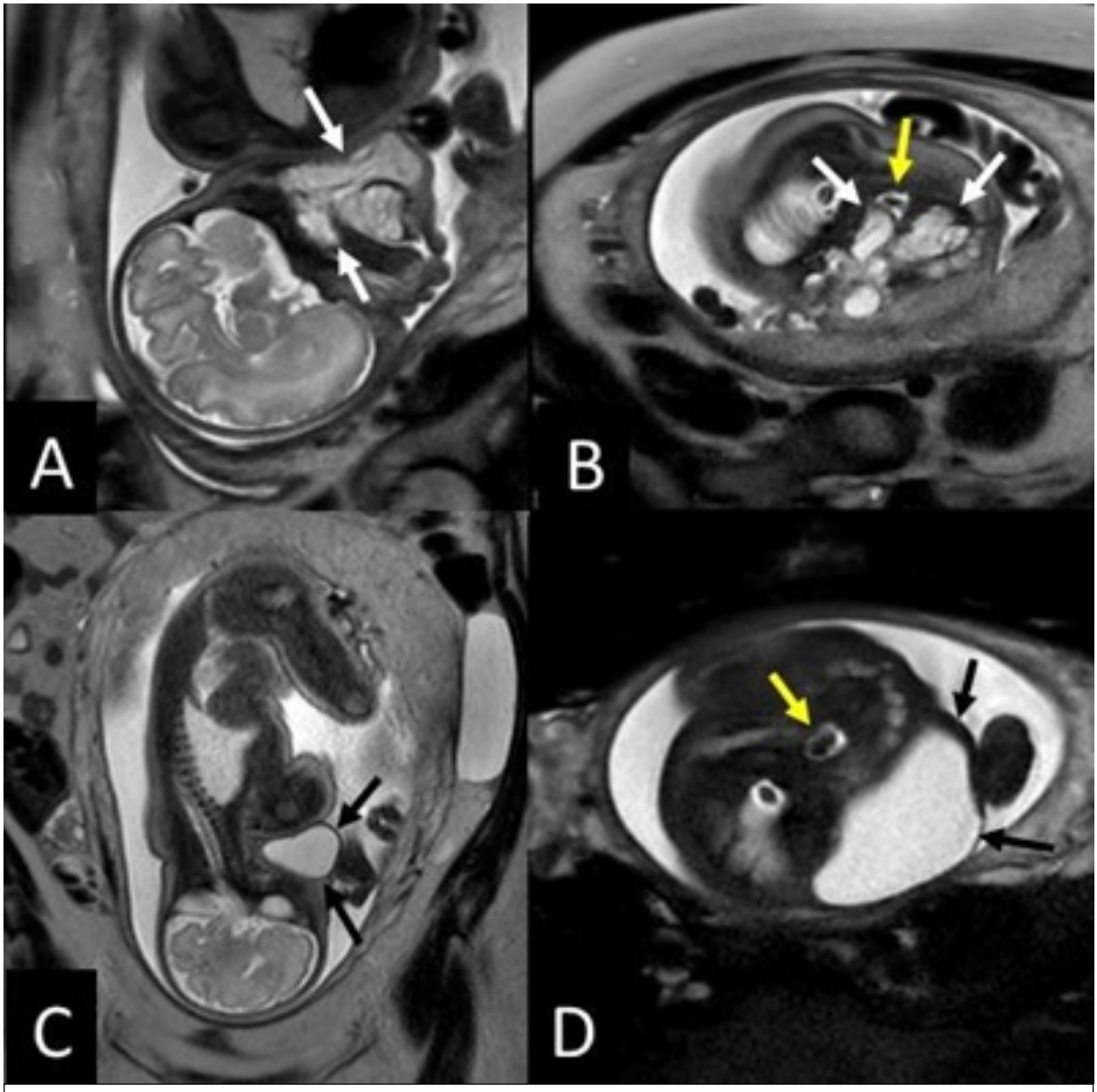

Fig 6: Fetal MRI. A, B T2WI, macrocystic LM of the neck involving submandibular and parapharyngeal space (white arrows) with compromise of the upper airway (yellow arrow), EXIT was needed. C, D T2 & Stir WI showing a submandibular and bucall spaces (black arrows) without upper airway involvement (yellow arrow). Courtesy of Gino Marisio MD, ENT surgeon. General Hospital of Concepción, Chile.

(after puncture extraction of as much fluid as possible) generates endothelial damage, inflammation, thrombotic vascular occlusion and sclerosis, which allows regression of the lesion. Several agents are used, most notably bleomycin and OK-432, but the use of doxycycline, ethanol and hypertonic glucose solution has also been described. It is usually a well-tolerated and responsive procedure, but may require several injections of the sclerosing agent. Reduction in the size of the macrocystic and microcystic components may be observed along with fibrotic changes both at the periphery and within the lesion, represented by a low signal on T2WI sequences. In general, complications are rare, usually with inflammatory response, flu-like symptoms and skin induration at the injection site. Given the above, several authors propose the use of sclerotherapy as the first line of treatment, either alone or in association with surgical resection after its use (1,9,13,15,18,21, 25,36,39).

The literature also mentions the oral administration of Sirolimus (rapamycin), a natural macrolide that is a specific inhibitor of the mammalian target of rapamycin (mTOR), a key serine/threonine kinase in the regulation of angiogenesis, cell growth and proliferation. Sirolimus, because of its antiangiogenic and antiproliferative properties,

could be an effective treatment in children with complicated large LM of the head and neck because of its potential to improve symptoms and reduce LM size (24,30,36,39).

If the LM is located proximal to the airway, ex-utero intrapartum therapy (EXIT) can be performed to keep the neonatal airway patent under placental support. Because of the greater potential for complications compared to a standard cesarean section, the decision to perform an EXIT is based on diagnostic imaging, where magnetic resonance imaging (MRI) is a valuable tool to accurately determine the extent and anatomic relationships of the LM to adjacent structures (Fig.6) (26,40).

Conclusions

In summary, the diagnosis and treatment of the head and neck LM remain a challenge for clinicians who have to decide whether or not to treat symptomatic and asymptomatic LMs that cause cosmetic concerns. Therefore, imaging tools play a fundamental role in determining the extent and critical anatomic relationships of the lesion that is essential for a correct treatment plan and adequate follow-up. Regarding treatment, although there is no consensus, multi modal treatment (surgery, sclerotherapy, radio-frequency ablation, etc.) is the best option to achieve an adequate result in terms of local control and resolution of the cosmetic aspects derived from these benign lesions.

Correspondence to:

Ilson Sepulveda Aguilar, DDS, MSc

Head & Neck Neuroradiologist
Master in Oncologic Imaging (Unipi)
Center for Studies and Innovation in Dentistry, School of Dentistry, Finis Terrae University
Santiago, Chile
Radiology Department
Otorhinolaryngology, Head & Neck Surgery and Maxillofacial Services
General Hospital of Concepción
San Martín Av. n° 1436, Concepción, Chile.
Phone: +56 41 2722749
Email: isepulvedaa@uft.edu

UNIVERSIDAD Finis Terrae

SERVICIO DE OTORRINOLARINGOLOGÍA Y CIRUGÍA DE CABEZA Y CUELLO
Hospital Guillermo Grant Benavente

Conflict of interest:

The authors declare that there were no conflicts of interest within the meaning of the recommendations of the International Committee of Medical Journal Editors when the article was written.

Disclaimer/Publisher's Note:

The statements, opinions and data contained in all publications are solely those of the individual author(s) and contributor(s) and not of Swiss J. Radiol. Nucl. Med. and/or the editor(s). Swiss J. Radiol. Nucl. Med. and/or the editor(s) disclaim responsibility for any injury to people or property resulting from any ideas, methods, instructions or products referred to in the content.

License Policy:

This work is licensed under a Creative Commons Attribution 4.0 International License. This license requires that reusers give credit to the creator. It allows reusers to distribute, remix, adapt, and build upon the material in any medium or format, even for commercial purposes.

SJORANM-LinkedIn:

Check out our journal's *LinkedIn* profile with over 6.000 registered followers from the Radiologic & Nuclear Medicine Imaging field: https://www.linkedin.com/in/sjoranm-swiss-j-radiol-nucl-med-4b00b427a/

References

1. Ma J, Biao R, Lou F, Lin K, Gao YQ, Wang ML, et al. Diagnosis and surgical treatment of cervical macrocystic lymphatic malformations in infants. Exp Ther Med. 2017 Aug 1;14(2):1293–8. https://doi.org/10.3892/etm.2017.4703.

2. Sun RW, Tuchin V V., Zharov VP, Galanzha EI, Richter GT. Current status, pitfalls and future directions in the diagnosis and therapy of lymphatic malformation. Vol. 11, Journal of Biophotonics. Wiley-VCH Verlag; 2018. https://doi.org/10.1002/jbio.201700124.

3. Bouatay R, Hmida B, Hajjej M, Farhati A, Harrathi K, Kolsi N, et al. Cervicofacial lymphatic malformations: diagnosis and management. Egyptian Journal of Otolaryngology. 2021 Dec 1;37(1). https://doi.org/10.1186/s43163-021-00143-4

4. Gnanavel A, Divya P, Vikram T. Cystic Hygroma - A Case Report and its Embryological Basis. Anatomy & Physiology. 2015;05(01). https://www.longdom.org/open-access/cystic-hygroma-a-case-report-and-its-embryological-basis-21777.html

5. Castel P, Carmona FJ, Grego-Bessa J, Berger MF, Viale A, Anderson K V., et al. Somatic PIK3CA mutations as a driver of sporadic venous malformations. Sci Transl Med. 2016 Mar 30;8(332). https://www.science.org/doi/10.1126/scitranslmed.aaf1164.

6. Mulliken JB, & GJ. Hemangiomas and Vascular Malformations in Infants and Children. Plast Reconstr Surg. 1982;69(3):412–20. https://journals.lww.com/plasreconsurg/abstract/1982/03000/hemangiomas_and_vascular_malformations_in_infants.2.aspx.

7. De Serres LM, Sie KCY, Richardson MA. Lymphatic Malformations of the Head and Neck A Proposal for Staging [Internet]. Vol. 121, Arch Otolaryngol Head Neck Surg. 1995. Available from: http://archotol.jamanetwork.com/ https://doi.org/10.1001/archotol.1995.01890050061012.

8. Li J, Zhong W, Geng X, Liu X, Zhang X, Wang Y, et al. Ultrasonographic diagnosis, classification, and treatment of cervical lymphatic malformation in paediatric patients: A retrospective study. BMC Pediatr. 2020 Sep 19;20(1). https://doi.org/10.1186/s12887-020-02337-w.

9. Snyder EJ, Sarma A, Borst AJ, Tekes A. Lymphatic Anomalies in Children: Update on Imaging Diagnosis, Genetics, and Treatment. AJR Am J Roentgenol. 2022 Jun;218(6):1089-1101. https://doi.org/10.2214/AJR.21.27200.

10. Romeo V, Maurea S, Mainenti PP, Camera L, Aprea G, Cozzolino I, et al. Correlative imaging of cystic lymphangiomas: ultrasound, CT and MRI comparison. Acta Radiol Open. 2015 May 1;4(5) https://doi.org/10.1177/2047981614564911.

11. Chen W, Xu H, Lina Z, Xu M, Li X, Sun G. The value of MRI in the diagnosis of pediatric head and neck lymphatic malformations: A study of 46 surgical cases. Eur J Radiol. 2024 Jan 1;170. https://doi.org/10.1016/j.ejrad.2023.111260.

12. de Leacy R, Bageac D V., Manna S, Gershon BS, Kirke D, Shigematsu T, et al. A radiologic grading system for assessing the radiographic outcome of treatment in lymphatic and lymphatic-venous malformations of the head and neck. American Journal of Neuroradiology. 2021 Oct 1;42(10):1859–64. https://doi.org/10.3174/ajnr.A7260.

13. Lerat J, Mounayer C, Scomparin A, Orsel S, Bessede JP, Aubry K. Head and neck lymphatic malformation and treatment: Clinical study of 23 cases. Eur Ann Otorhinolaryngol Head Neck Dis. 2016 Dec 1;133(6):393–6. https://doi.org/10.1016/j.anorl.2016.07.004.

14. Oosthuizen JC, Burns P, Russell JD. Lymphatic malformations: A proposed management algorithm. Int J Pediatr Otorhinolaryngol. 2010 Apr; 74(4):398–403. https://doi.org/10.1016/j.ijporl.2010.01.013.

15. Colbert SD, Seager L, Haider F, Evans BT, Anand R, Brennan PA. Lymphatic malformations of the head and neck - current concepts in management. British Journal of Oral and Maxillofacial Surgery. 2013;51(2):98–102. https://doi.org/10.1016/j.bjoms.2012.02.004.

16. Wiegand S, Wichmann G, Dietz A, Werner JA. Association between malformation type, location and functional deficits in lymphatic malformations of the head and neck in children. Eur Arch Otorhinolaryngol. 2023 May;280(5):2535-2540. https://doi.org/10.1007/s00405-023-07844-x.

17. Adams MT, Saltzman B, Perkins JA. Head and neck lymphatic malformation treatment: a systematic review. Otolaryngol Head Neck Surg. 2012 Oct; 147(4):627-39. https://doi.org/10.1177/0194599812453552

18. Grasso DL, Pelizzo G, Zocconi E, Schleef J. Lymphangiomas of the head and neck in children. Acta Otorhinolaryngol Ital. 2008 Feb;28 (1):17-20. https://pmc.ncbi.nlm.nih.gov/articles/PMC2640069/.

19. Perkins JA. New Frontiers in Our Understanding of Lymphatic Malformations of the Head and Neck: Natural History and Basic Research. Otolaryngol Clin North Am. 2018 Feb;51(1):147-158. https://doi.org/10.1016/j.otc.2017.09.002.

20. Konuthula, Neeraja; Bindschadler, Michael; Perez, Francisco A; Shivaram, Giri M; Bly, Randall A; Friedman, Seth D; Perkins, Jonathan A. Quan-tifying Head and Neck Lymphatic Malformation Volume and Composition During Treatment. Journal of Vascular Anomalies 3(1):p e037, March 2022. https://doi.org/10.1097/JOVA.0000000000000037.

21. Wu C, Song D, Guo L, Wang L. Refractory Head and Neck Lymphatic Malformation in Infants Treated With Sirolimus: A Case Series. Front Oncol. 2021 Jul 16;11:616702. https://doi.org/10.3389/fonc.2021.616702.

22. De Maria L, De Sanctis P, Balakrishnan K, Tollefson M, Brinjikji W. Sclerotherapy for lymphatic malformations of head and neck: Systematic review and meta-analysis. J Vasc Surg Venous Lymphat Disord. 2020 Jan;8(1):154-164. https://doi.org/10.1016/j.jvsv.2019.09.007.

23. Lal A, Gupta P, Singhal M, Sinha SK, Lal S, Rana S, Khandelwal N. Abdominal lymphatic malformation: Spectrum of imaging findings. Indian J Radiol Imaging. 2016 Oct-Dec;26(4):423-428. https://doi.org/10.4103/0971-3026.195777.

24. Wiegand S, Dietz A, Wichmann G. Efficacy of sirolimus in children with lymphatic malformations of the head and neck. Eur Arch Otorhinolaryngol. 2022 Aug;279(8):3801-3810. https://doi.org/10.1007/s00405-022-07378-8.

25. Larson AS, Brinjikji W, Anderson KR, Tollefson M, Michelle Silvera V, Guerin JB. Imaging of benign cervicofacial vascular anomalies and associated syndromes. Interv Neuroradiol. 2022 Jun;28(3):364-374 https://doi.org/10.1177/15910199211034989.

26. Bouwman FCM, Klein WM, de Blaauw I, Woiski MD, Verhoeven BH, Botden SMBI. Lymphatic malformations adjacent to the airway in neonates: Risk factors for outcome. J Pediatr Surg. 2021 Oct;56(10):1764-1770. https://doi.org/10.1016/j.jpedsurg.2021.03.011.

27. Vrinceanu D, Dumitru M, Marinescu A, Dorobat B, Palade OD, Manole F, Muresian H, Popa-Cherecheanu M, Ciornei CM. New Insights into Cervicofacial Vascular Anomalies. J Clin Med. 2024 Jun 15;13(12):3515. https://doi.org/10.3390/jcm13123515.

28. Dhagat PK, Jain M, Farooq A. MRI evaluation of soft tissue vascular malformations. Indian J Radiol Imaging. 2020 Apr-Jun;30(2):184-189. https://doi.org/10.4103/ijri.IJRI_439_19.

29. Iwai T, Minamiyama S, Sugiyama S, Mitsudo K. Lymphatic malformation in the buccal region. Eur Ann Otorhinolaryngol Head Neck Dis. 2022 Oct;139(5):313-314. https://doi.org/10.1016/j.anorl.2021.12.005.

30. Gupta R, Bhandari A, Navarro OM. Pediatric Vascular Anomalies: A Clinical and Radiological Perspective. Indian J Radiol Imaging. 2023 Sep 16;34(1):103-127. https://doi.org/10.1055/s-0043-1774391.

31. Crivelli L, Millischer AE, Sonigo P, Grévent D, Hanquinet S, Vial Y, Alamo L. Contribution of magnetic resonance imaging to the prenatal diagnosis of common congenital vascular anomalies. Pediatr Radiol. 2021 Aug;51(9):1626-1636. https://doi.org/10.1007/s00247-021-05031-w.

32. Cronan J, Gill AE, Shah JH, Hawkins CM. The Role of Interventional Radiologists in the Treatment of Congenital Lymphatic Malformations. Semin Intervent Radiol. 2020 Aug;37(3):285-294. https://doi.org/10.1055/s-0040-1713446.

33. Lee S, Ko SY, Park WJ. Macrocystic lymphatic malformation of the chest wall and axilla: A case report in a 45-year-old man. Radiol Case Rep. 2021 Nov 10;17(1):152-155. Erratum in: Radiol Case Rep. 2023 Feb 09;18(4):1652. https://doi.org/10.1016/j.radcr.2021.10.001.

34. Brahmbhatt AN, Skalski KA, Bhatt AA. Vascular lesions of the head and neck: an update on classification and imaging review. Insights Imaging. 2020 Feb 7;11(1):19. https://doi.org/10.1186/s13244-019-0818-3.

35. Schmidt VF, Masthoff M, Czihal M, Cucuruz B, Häberle B, Brill R, Wohlgemuth WA, Wildgruber M. Imaging of peripheral vascular malformations - current concepts and future perspectives. Mol Cell Pediatr. 2021 Dec 7;8(1):19. https://doi.org/10.1186/s40348-021-00132-w.

36. Bhari N, Agarwal A, Asritha CVV, Panda M, Mahajan R. Vascular Malformations. Indian Dermatol Online J. 2024 Apr 23;15(3):415-430. https://doi.org/10.4103/idoj.idoj_633_23.

37. Embrechts JLA, Hiddinga S, Bot JC, Hendrickx JJ, van Eekelen R, Ket JCF, Leemans CR, de Bree R. Surgery versus sclerotherapy versus combined therapy in head and neck lymphatic malformations in the pediatric population: systematic review and meta-analysis. Eur Arch Otorhinolaryngol. 2024 Sep;281(9):4529-4539. https://doi.org/10.1007/s00405-024-08661-6.

38. Healy J, Balcazar JA, Rivera L, Ruas V. Rapid lymphatic malformation expansion: Imaging, association with asymptomatic Streptococcus infection, multidisciplinary management, and therapeutic approach. Radiol Case Rep. 2023 Jun 26;18(9):3162-3168. https://doi.org/10.1016/j.radcr.2023.06.029.

39. Poget M, Fresa M, El Ezzi O, Saliou G, Doan MT, de Buys Roessingh A. Lymphatic malformations in children: retrospective review of surgical and interventional management. Pediatr Surg Int. 2022 Dec 5;39(1):36. https://doi.org/10.1007/s00383-022-05320-x.

40. Hyvönen H, Salminen P, Kyrklund K. Long-term outcomes of lymphatic malformations in children: An 11-year experience from a tertiary referral center. J Pediatr Surg. 2022 Dec;57(12):1005-1010. https://doi.org/10.1016/j.jpedsurg.2022.07.024.