Multimodality Imaging of Classical Dysplasia Epiphysealis Hemimelica (Trevor's Disease): A Case Report

Babu Peter Sathyanathan[1], Nandhini Gopi Bagya[1]

[1] Barnard Institute of Radiology, Madras Medical College, Chennai, Tamil Nadu, India

Corresponding author: Babu Peter Sathyanathan · drsbabupeter@gmail.com

ORCID · Babu Peter Sathyanathan: https://orcid.org/0000-0002-4057-0054

Received: 28 May 2024 · Published: 9 June 2024

Swiss Journal of Radiology and Nuclear Medicine · https://www.sjoranm.com · SJORANM GmbH · Switzerland

Abstract

Dysplasia epiphysealis hemimelica (DEH), also known as Trevor's disease, is a rare developmental disorder that can resemble an epiphyseal tumour. A 13-year-old boy presented with progressive swelling and pain involving the right knee and ankle and had initially been referred with a provisional diagnosis of chondrosarcoma. CT demonstrated multiple epiphyseal osteochondroma-like outgrowths involving the articular surfaces of the knee and ankle. MRI of the ankle demonstrated cortical and medullary continuity with the adjacent bones, medial predominance of the lesions and no surrounding oedema. Review of the radiographs, CT and MRI favoured classical DEH affecting a single lower limb. Biopsy of the distal femoral lesion was reported as osteochondroma, supporting the radiological diagnosis of DEH. This case illustrates the complementary contribution of multimodality imaging and radiological–pathological correlation to the assessment of an unusual epiphyseal lesion.

Keywords: Trevor's disease; dysplasia epiphysealis hemimelica; osteochondroma; magnetic resonance imaging

Introduction

Trevor's disease is a rare and severe debilitating disease affecting the epiphysis [1, 2, 3] of long bones causing bony outgrowths (osteochondroma like) with cartilaginous cap, when involving joint surface can result in severe disabling pain to the patient. Epiphyseal involvement can result in limb shortening and limb length discrepancy.

The diagnosis is usually achievable with computed tomography and X rays, but MRI helps in visualizing the cartilaginous cap, compression of adjacent neurovascular bundle and other soft tissue.

Case Report

The patient, a 13-year old male child, was referred to our radiology department as a radiologically diagnosed case of chondrosarcoma of right knee joint, with imaging done elsewhere. The patient had presented with a swelling over right knee joint developing slowly over a period of 2 years. The patient presented to the orthopaedic department with above mentioned complaints and after local examination, provisional diagnosis of chondrosarcoma of right knee joint was given. Clinical examination and detailed history taking revealed the chronic and benign course of the swelling. Upon closer examination, it became evident that the deformities also involved his right ankle joint. The patient was apparently healthy otherwise and had no antecedent history of trauma or systemic illnesses. The patient was then subjected to CT of right knee and ankle joints and MR right ankle joint.

Open Access · CC BY 4.0 · © 2024 The Author(s) · Published by SJORANM GmbH, Switzerland
ISSN 2813-7221 · Swiss J. Radiol. Nucl. Med. 2024 9(1):6-10 · DOI 10.59667/sjoranm.v9i1.14

Imaging of the Right Knee

CT of right knee joint revealed multiple sessile bony outgrowths arising from distal femoral epiphysis, patella and proximal tibial epiphysis involving articular surface. Florid pedunculated bony lesion with irregular surface arising from medial condyle of distal femur noted with multiple loose bodies seen within the right knee joint. (Figure 1a–d)

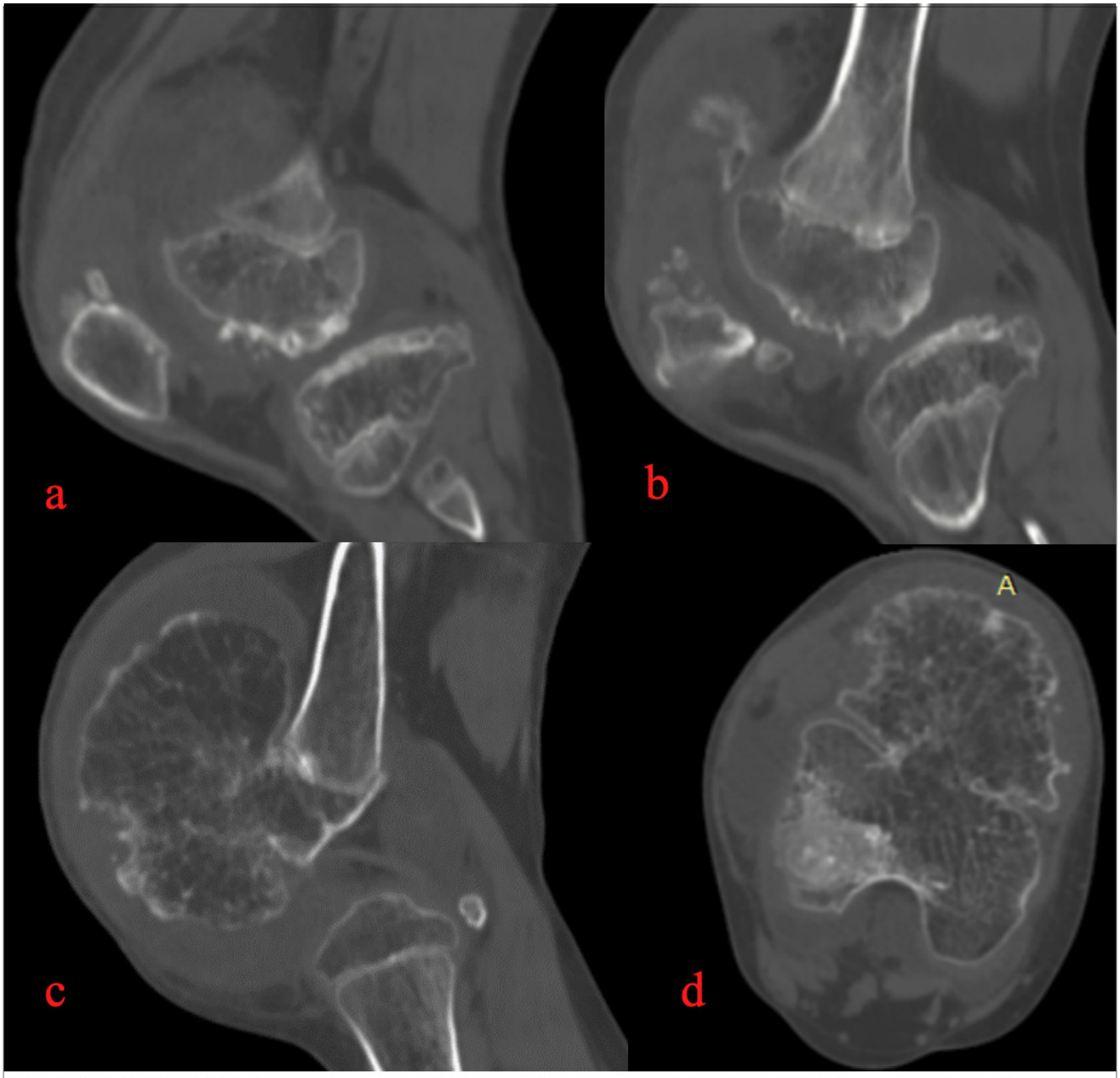

Fig.1: (a & b) CT of right knee showing multiple osteochondromas arising from tibial, femoral and patellar epiphysis of a 13 year old male child. (c & d) CT showing florid pedunculated osteochondroma arising from femoral epiphysis of the same child.

Figure 1. CT of the right knee, showing multiple epiphyseal osteochondroma-like outgrowths. Panels a–d.

Open Access · CC BY 4.0 · © 2024 The Author(s) · Published by SJORANM GmbH, Switzerland
ISSN 2813-7221 · Swiss J. Radiol. Nucl. Med. 2024 9(1):6-10 · DOI 10.59667/sjoranm.v9i1.14

Imaging of the Right Ankle and Foot

CT of right ankle joint revealed multiple sessile bony outgrowths arising from distal tibial epiphysis, articular surfaces of talus involving tibiotalar, talocalcaneal and talonavicular joints, navicular and cuneiform bones. (Figure 2d,e)

MR ankle showed medullary and cortical continuity between the lesions and the adjacent bones with medial predominance of the lesions and no surrounding edema. (Figure 2a,b)



Fig.2: (a) T1 & (b) PD fat saturated sequence of right ankle joint showing multiple osteochondromas arising from the epiphysis of right tibia, talus and navicular bones. (c) radiograph of right ankle joint. (d) & (e) CT showing multiple osteochondromas arising from bones of right foot

Figure 2. Multimodality images of the right ankle and foot: MRI (a,b), radiograph (c) and CT (d,e).

Open Access · CC BY 4.0 · © 2024 The Author(s) · Published by SJORANM GmbH, Switzerland
ISSN 2813-7221 · Swiss J. Radiol. Nucl. Med. 2024 9(1):6-10 · DOI 10.59667/sjoranm.v9i1.14

Radiological Diagnosis and Biopsy

The initial assessment was influenced by the referral diagnosis of chondrosarcoma. Review of the radiographs, CT and MRI identified multiple epiphyseal outgrowths involving the right knee and ankle, cortical and medullary continuity with adjacent bones, and predominantly medial involvement of one limb. These findings favoured classical dysplasia epiphysealis hemimelica.

Biopsy of the prominent distal femoral epiphyseal outgrowth was performed. The histological report described osteochondroma, supporting the radiological diagnosis of dysplasia epiphysealis hemimelica (Figure 3).

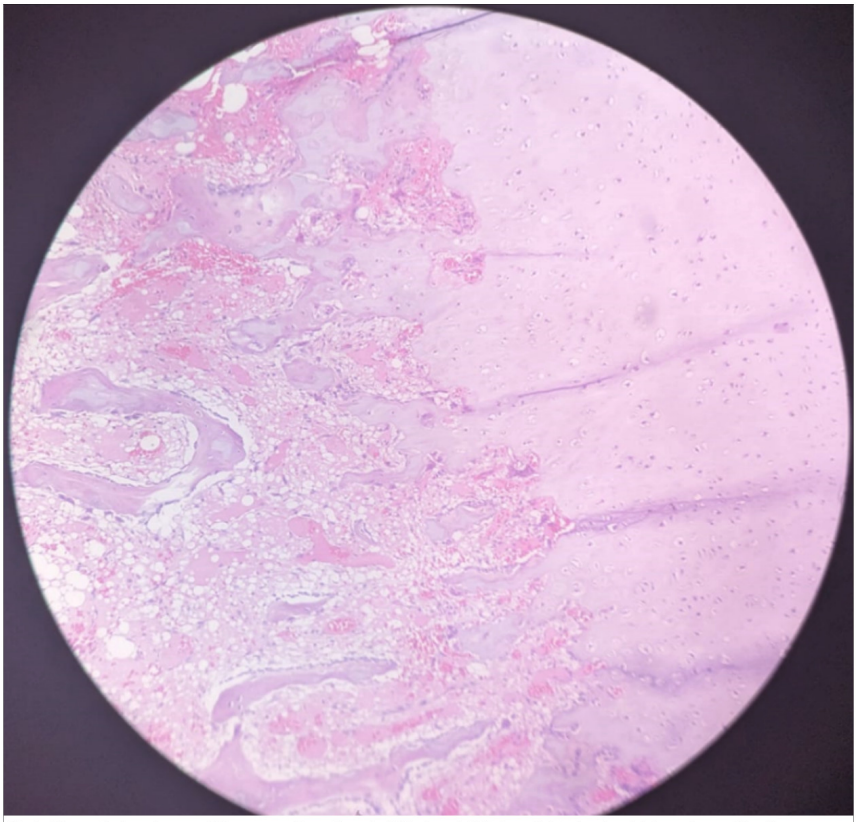

Fig.3: Histopathology image of biopsy specimen from florid lesion of right knee joint showing thickened cap of hyaline cartilage with underlying bony trabeculae suggestive of osteochondroma

Figure 3. Histology of the biopsy from the distal femoral epiphyseal lesion, reported as osteochondroma and supporting the radiological diagnosis of DEH.

Discussion

Plain Radiography

The typical appearance is of asymmetric epiphyseal cartilaginous overgrowth, containing multiple ossific centres. The pattern of epiphyseal chondral calcification may be stippled, irregular, or dense. Metaphyseal widening and remodelling may occur. The ossification centres of affected bones typically appear early, and premature closure of the affected epiphysis may occur. The resulting limb length inequality, joint incongruity, and articular surface irregularity predisposes to early onset osteoarthritis.

Computed Tomography

CT demonstrates the typical chondroid nature of the calcifications, medullary continuity and will identify cortical irregularity of the lesion, or that secondary to degenerative changes within the joint. The multiplanar reformatting capability of CT allows detailed evaluation of the extent of joint involvement and is a valuable tool for surgical planning [4, 5, 6].

Open Access · CC BY 4.0 · © 2024 The Author(s) · Published by SJORANM GmbH, Switzerland
ISSN 2813-7221 · Swiss J. Radiol. Nucl. Med. 2024 9(1):6-10 · DOI 10.59667/sjoranm.v9i1.14

Magnetic Resonance Imaging

MRI can depict the cartilaginous component of the lesion, epiphyseal involvement, articular deformity and associated soft-tissue changes. In the present case, MRI contributed to interpretation of the radiographs and CT findings. The complementary information from these modalities and the biopsy supported the final diagnostic assessment [7].

The cartilage cap of the lesion has T2 hyperintensity and intermediate signal intensity on T1-weighted sequences. Focal areas of dense calcification within the marrow may be seen as signal voids on T1 and T2- weighted sequences.

Conclusion

Classical dysplasia epiphysealis hemimelica should be considered in a child with asymmetric epiphyseal osteochondroma-like lesions involving several bones of one lower limb. Radiographs, CT and MRI provide complementary information about mineralized and cartilaginous components, joint involvement and adjacent soft tissues. In this case, multimodality review and biopsy supported the diagnosis. The case illustrates diagnostic correlation and does not establish a universal sequence for CT and MRI.

Correspondence

Prof. Dr. Babu Peter Sathyanathan · Professor of Radiology · Barnard Institute of Radiology · Madras Medical College · Rajiv Gandhi General Hospital · Opposite Chennai Central Railway Station · Chennai, Tamil Nadu, India · drsbabupeter@gmail.com

Phone: +91 9444366278; +91 9790327903

Conflict of Interest

The authors declare that there were no conflicts of interest within the meaning of the recommendations of the International Committee of Medical Journal Editors when the article was written.

Disclaimer and Publisher's Note

The statements, opinions and data contained in all publications are solely those of the individual author(s) and contributor(s) and not of Swiss J. Radiol. Nucl. Med. and/or the editor(s). Swiss J. Radiol. Nucl. Med. and/or the editor(s) disclaim responsibility for any injury to people or property resulting from any ideas, methods, instructions or products referred to in the content.

This work is licensed under the Creative Commons Attribution 4.0 International License: https://creativecommons.org/licenses/by/4.0/

References

1. Trevor D. Tarso-epiphysial aclasis; a congenital error of epiphysial development. J Bone Joint Surg Br. 1950;32-B:204–213. https://doi.org/10.1302/0301-620X.32B2.204
2. Fairbank TJ. Dysplasia epiphysialis hemimelica (tarso-epiphysial aclasis). J Bone Joint Surg Br. 1956;38-B:237–257. https://doi.org/10.1302/0301-620X.38B1.237
3. Smith EL, Raney EM, Matzkin EG, Fillman RR, Yandow SM. Trevor's disease: the clinical manifestations and treatment of dysplasia epiphysealis hemimelica. J Pediatr Orthop B. 2007;16:297–302. https://doi.org/10.1097/BPB.0b013e328092563f
4. Arealis G, Nikolaou VS, Lacon A, Ashwood N, Hayward K, Karagkevrekis C. Trevor's disease: a literature review regarding classification, treatment, and prognosis apropos of a case. Case Rep Orthop. 2014;2014:940360. https://doi.org/10.1155/2014/940360
5. Shinozaki T, Ohfuchi T, Watanabe H, Aoki J, Fukuda T, Takagishi K. Dysplasia epiphysealis hemimelica of the proximal tibia showing epiphyseal osteochondroma in an adult. Clin Imaging. 1999;23:168–171. https://doi.org/10.1016/S0899-7071(99)00124-2
6. Gökkuş K, Atmaca H, Sagtas E, Saylik M, Aydin AT. Trevor's disease: up-to-date review of the literature with case series. J Pediatr Orthop B. 2017;26:532–545. https://doi.org/10.1097/BPB.0000000000000269
7. Peduto AJ, Frawley KJ, Bellemore MC, Kuo RS, Foster SL, Onikul E. MR imaging of dysplasia epiphysealis hemimelica: bony and soft-tissue abnormalities. AJR Am J Roentgenol. 1999;172(3):819–823. https://doi.org/10.2214/ajr.172.3.10063889