

Bilateral Ovarian Goitre: Case Report and Review of the Literature

Assia Seddouki¹, Sofia Chkikar¹, Nadia Ismaili Alaoui¹

¹Department of Nuclear Medicine, Hassan II University Hospital Center, Fez, Morocco

Swiss Journal of Radiology and Nuclear Medicine - www.sjoranm.com - SJORANM GmbH - CH-3072 Ostermundigen bei Bern - Switzerland

Abstract

Ovarian goitre is classified within the category of single-tissue teratomas and represents a rare subtype of ovarian tumor. The histological identification of malignant variants has historically been contentious and inadequately assessed, primarily due to the lack of standardized diagnostic criteria and the tumor's infrequency. We present a case involving bilateral metastatic struma ovarii initially managed with conservative surgery, involving cystectomy on one side and radical oophorectomy on the other, as it was initially deemed benign. However, malignant transformation occurring seven years later necessitated a subsequent surgical intervention and adjunctive iratherapy.

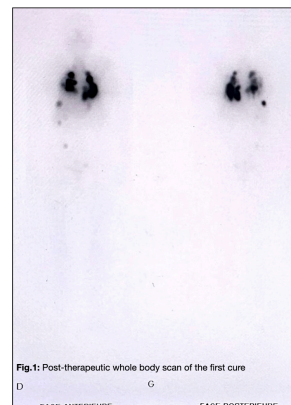


Fig. 1: Post-therapeutic whole body scan of the first cure
D FACE ANTERIEURE G FACE POSTERIEURE

Keywords: Ovarien goitre, ovarian tumour, struma ovarii, teratoma, iratherapy, differentiated thyroid tissue

¹Corresponding author: [Assia Seddouki](mailto:Assia.Seddouki) - received: 21.04.2024 - peer reviewed, accepted and published: 02.05.2024

Introduction

Ovarian goitre, also known as struma ovarii, primarily represents an anatomopathological entity characterized by the presence of differentiated thyroid tissue within the ovary, typically categorized as a mature monodermal teratoma. Consequently, the spectrum of anatomo-pathological and functional manifestations of ovarian goitres mirrors that of thyroid pathology itself, encompassing benign lesions, potentially malignant lesions, instances of metastasis, and the occurrence of hyperthyroidism (1). The majority of struma ovarii cases are benign and typically unilateral, with only 5% to 10% exhibiting malignant features (2).

Objective


This report presents a case of bilateral ovarian goitre, accompanied by an analysis of clinical and biological parameters, morphological and isotopic imaging characteristics, and anatomo-pathological aspects. Additionally, various manage-

ment methods are discussed, along with a comprehensive review of the existing literature.

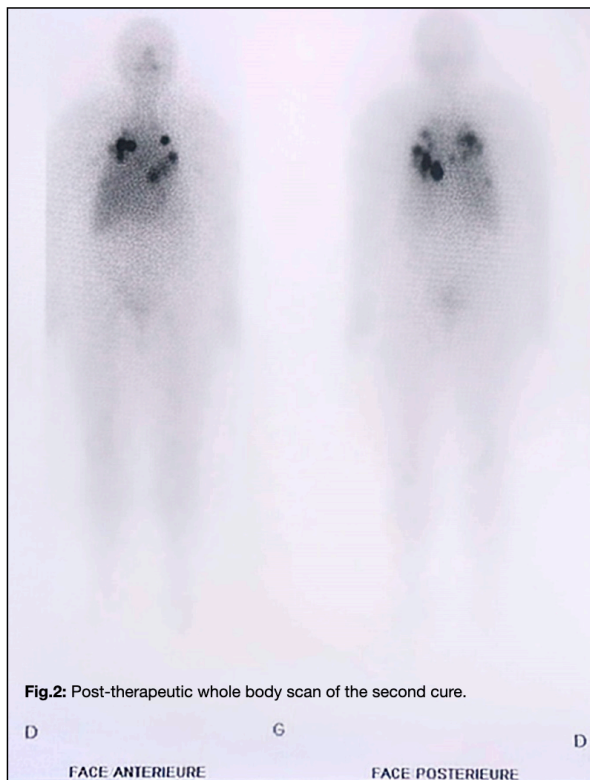Patient and Observation

The patient, aged 38, was biparous (having given birth to two children via cesarean section due to pelvic narrowing), hypertensive, and diabetic, managed with dietary measures and had no significant personal or family history of thyroid disorders. In 2014, she presented with pelvic pain, leading to consultation with a gynecologist. Subsequent evaluation revealed an ovarian mass, prompting left adnexectomy and resection of a right ovarian cyst. Pathological examination confirmed left ovarian goitre and a right dermoid cyst, both benign.

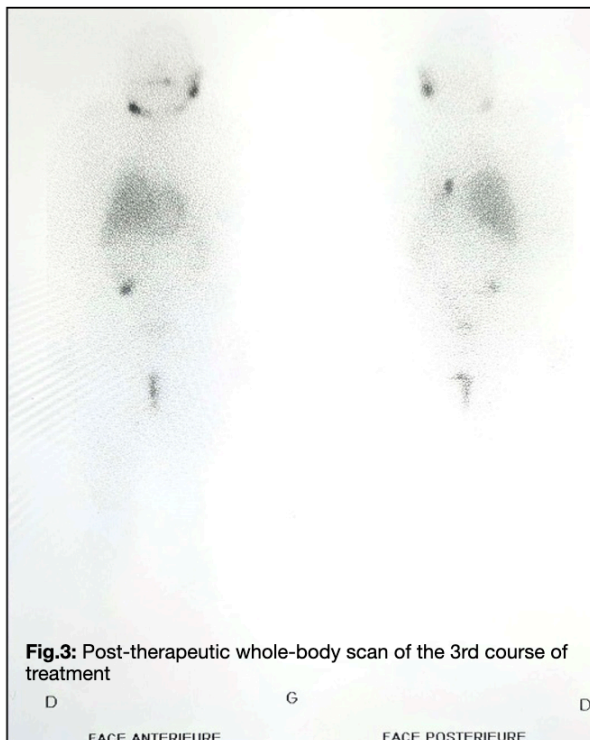
Three years later, the patient developed Graves' disease, diagnosed through TSH receptor antibody testing and thyroid scintigraphy. Following a relapse, she underwent radioiodine therapy (444 MBq) supplemented with Levothyroxine. In 2018, she experienced intermittent right hypochondrial pain and spontaneous hemoptysis, prompting a



thoraco-abdominal-pelvic (TAP) scan in 2021. Imaging revealed multiple nodular and micro-nodular pulmonary parenchymal lesions, hyper-

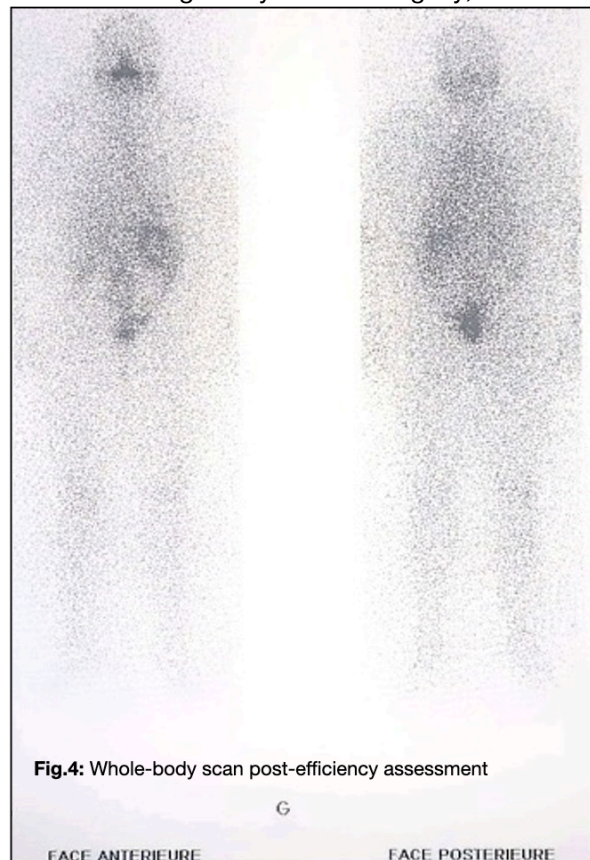


vascular liver nodules, and a pelvic cyst. A CT-guided lung biopsy confirmed metastatic thyroid



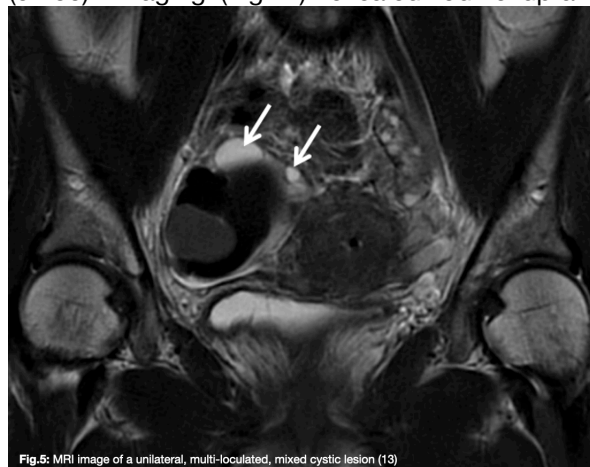
carcinoma, while pelvic MRI suggested a suspicious right ovarian cyst. Given the clinical history, a right adnexectomy was performed, revealing thyroid tissue suggestive of secondary thyroid carcinoma. Subse-

quently, total thyroidectomy with bilateral lymph node dissection was performed. Histopathological examination indicated microvesicular adenoma and dystrophic thyroid parenchyma without malignancy. Post-surgery, elevated



Thyroglobulin (Tg) levels (>1000) and positive anti-Tg antibodies (ATg) (237.90) were noted.

Four months later, high-dose radioiodine therapy (5GBq) was administered after Thyrogen stimulation. Peri-therapeutic evaluation showed decreased Tg levels (>10000) and negative ATg (51.80). Imaging (Fig. 1) revealed iodine uptake



in pulmonary and hepatic lesions and a pelvic mass. A second radioiodine therapy (3.7 GBq) was administered after six months (Fig. 2), showing regression of pulmonary and hepatic



lesions on imaging. Follow-up MRI revealed no abnormalities.

Nine months later, the patient received a third radioiodine therapy (3.7 GBq) after L-thyroxine withdrawal. Post-therapy imaging demonstrated regression of lesions (Fig. 3).

One year later, the patient underwent a follow-up assessment to evaluate treatment efficacy, with peri-therapeutic measurements showing TSH suppression (TSHus) at 232.05, Thyroglobulin (Tg) at 0.35, and negative anti-Thyroglobulin antibodies (ATg) at 7.30. Scintigraphic imaging displayed a uniform distribution of radioactivity (Fig. 4). The patient has been declared cured and is currently undergoing regular biological monitoring while receiving a reduced dosage of Levothyroxine, aiming to achieve a target TSH suppression level below 0.1.

Tumors originating from pluripotent germ cells
<p>The term "teratoma" encompasses a group of intricate tumors originating from pluripotent germ cells, derived from embryonic layers. These tumors typically consist of varying proportions of three embryonic tissue types:</p> <ul style="list-style-type: none"> • <i>Ectodermal</i> tissue, derived from the skin and nervous system • <i>Mesodermal</i> tissue, derived from fat, bone, and cartilage • <i>Endodermal</i> tissue (less frequently), derived from gastrointestinal and bronchial tissue.
<p><small>Tab. 1: Complex tumours developed from embryonic leaves [3]</small></p>

Discussion:

The term "teratoma" encompasses a group of intricate tumors originating from pluripotent germ cells, derived from embryonic layers. These tumors typically consist of varying proportions of three embryonic tissue types (Tab.1):

- *Ectodermal tissue, derived from the skin and nervous system*
- *Mesodermal tissue, derived from fat, bone, and cartilage*
- *Less frequently, endodermal tissue, derived from gastrointestinal and bronchial tissue.*

Teratomas are among the most common tumors in young women, predominantly found in the ovaries but occasionally observed in locations such as the brain (pituitary or pineal gland), mediastinum, or retroperitoneum. While teratomas may sometimes occur bilaterally (3), they are typically unilateral (Tab. 2).

There are three main types of teratomas:

- *Mature teratomas, also known as dermoid cysts, are benign, slow-growing tumors.*


- *Immature teratomas are rare malignant tumors that grow rapidly and exhibit varying degrees of aggressiveness, as determined by histopathological examination.*
- *Monodermal teratomas are much less common.*

Ovarian goiters, first described by Von Kalden in 1895 and Gottschalk in 1899 (4), are single-tissue teratomas predominantly composed (more than 50% of the tumor) or exclusively (pure ovarian goiter) of thyroid tissue (2). Thyroid tissue within these tumors can be normal, hyperplastic, or, rarely, neoplastic, with the latter referred to as struma ovarii (5).

While most ovarian goiters are benign, malignant transformation, known as "malignant ovarian goiter," is exceedingly rare, occurring in less than 1% of cases, typically in individuals around 50 years of age with extremes of 26 and 77 years (6). Diagnosis of ovarian goiters is often incidental, although symptoms (4) such as abdomino-pelvic mass, acute abdominal pain, hyperthyroidism (6), abnormal uterine bleeding, ascites, or features of Meigs syndrome (8) may prompt evaluation. Ovarian goitre is most often diagnosed during a routine examination or in the presence of symptoms (4), essentially an abdomino-pelvic mass in 78% of cases, acute abdominal pain in 22% of cases and, more rarely, signs of hyperthyroidism (6) and abnormal uterine bleeding; ascites occurs in a third of cases, and some patients may show features of Meigs syndrome (8) (the combination of a benign ovarian tumour, ascites and pleurisy). The literature reports that if a mass was present, it often involved the left ovary (7). Occasionally, a secretory ovarian goitre may cause the hypothalamic-pituitary axis to rest, with a risk of postoperative hypothyroidism. A few cases of ovarian goitre with manifestations of autoimmunity such as Hashimoto's disease or Graves' disease have been reported (2).

There are 3 Main Types of Teratomas
<p>Teratomas are one of the most common tumours in young women, mostly located in the ovaries, but can occasionally be seen in the brain in the pituitary or epiphysis, or even in the mediastinum or retroperitoneum. Teratomas are sometimes bilateral (3):</p> <ul style="list-style-type: none"> • <i>Mature teratomas, also known as dermoid cysts, are benign, slow-growing tumors</i> • <i>Immature teratomas are rare malignant tumors that grow rapidly and exhibit varying degrees of aggressiveness, as determined by histopathological examination</i> • <i>Monodermal teratomas are much less common</i>
<p><small>Tab. 2: Different main types of Teratomas [3]</small></p>

Imaging modalities such as ultrasound, CT, and MRI can aid in the differentiation and diagnosis of



ovarian teratomas. Radiological characteristics described by Kim et al. (9) include a complex multi-lobulated mass with thickened septa, multiple cysts of varying signal intensity, and solid components. Enhancement of solid portions following gadolinium injection corresponds to thyroid tissue and stroma with abundant vascularization and fibrous tissue (8, 9).

In terms of pathological diagnosis, Devaney et al. concluded that the criteria for diagnosing malignant struma ovarii should align with those used for thyroid carcinoma (7). Only tumors exhibiting cytological features indicative of malignancy, such as irregular, overlapping, and ground-glass cell nuclei, intense mitotic activity, or signs of vascular invasion (10), should be classified as truly malignant and at risk of metastasis. Immunostaining for thyroglobulin serves to confirm the thyroid nature of the cellular component in poorly differentiated forms and aids diagnosis in approximately 16% of cases (6). The primary goal is to decrease disease incidence and prevent unnecessary treatments. Metastatic dissemination is rare, occurring in approximately 5% of cases, either through regional lymphatic routes to the pelvic and para-aortic lymph nodes or through direct extension to adjacent structures such as the omentum, peritoneal cavity, contralateral ovary, or hematogenously to distant sites including bone, lungs, liver, and brain (10).

De Simone et al. advocate for total thyroidectomy, which not only enables exclusion of a primary thyroid tumor metastasizing to the ovary but also facilitates systematic additional treatment with radioactive iodine and enhances subsequent monitoring. Their therapeutic line of action is supported by findings from the literature, indicating that all patients who received additional treatment with I^{131} achieved remission, whereas 50% of patients treated with ovarian surgery alone experienced recurrence. Additional treatment with ablative doses of I^{131} after total thyroidectomy is warranted in cases of locoregional tumor extension (13), distant metastases, or tumor recurrence (10).

The risk of recurrence, challenging to estimate given the limited number of reported series, is approximately 15% (12). Therefore, ongoing monitoring is recommended even for benign goiters due to the difficulty in definitively confirming benignity. This surveillance aims to detect local or metastatic tumor recurrence and relies on clinical monitoring, measurement of circulating thyroglobulin after TSH stimulation (endogenous

or exogenous), and increasingly, PET-CT imaging (11).

Conclusion:

Malignant ovarian goitre represents a rare ovarian tumor characterized by nonspecific clinical symptoms. Diagnosis of these tumors relies on histological examination, often presenting challenges, particularly in well differentiated forms. Treatment typically involves radical and extensive surgery for elderly patients, while young patients with localized tumors may benefit from conservative approaches. Although late recurrence with malignant transformation is uncommon, it remains a possibility, underscoring the importance of long-term monitoring. Given the rarity of malignant ovarian goiters, their management necessitates optimized coordination among multidisciplinary teams. Currently, radiotherapy (brachytherapy) is recommended in cases of residual tumor, recurrence, or metastasis.

Correspondence to

[Dr. Assia Seddouki](#)

Centre Hospitalier Universitaire Hassan II
Fès, Morocco, Centre Hospitalier Hrazem
BP:1835 Atlas, Fès, Avenue Hassan II
Fes 30050, Marokko



Conflict of interest:

The authors declare that there were no conflicts of interest within the meaning of the recommendations of the International Committee of Medical Journal Editors when the article was written.

Disclaimer/Publisher's Note:

The statements, opinions and data contained in all publications are solely those of the individual author(s) and contributor(s) and not of Swiss J. Radiol. Nucl. Med. and/or the editor(s). Swiss J. Radiol. Nucl. Med. and/or the editor(s) disclaim responsibility for any injury to people or property resulting from any ideas, methods, instructions or products referred to in the content.



References

- (1) <https://www.lequotidiendumedecin.fr/archives/lessentiel-sur-le-goitre-ovarien>
- (2) Lachiri, B., Benkerroum, Z., Allaoui, M., Abdel-gheni, Z., Guelzim, K., Kouach, J., Dehayni, M. (2015). Goitre ovarien bénin: à propos d'un cas et revue de la littérature. Pan African Medical Journal, 21. doi: <https://www.ajol.info/index.php/pamj/article/view/132700>
- (3) [Tératome ovarien](https://www.deuxiemeavis.fr/pathologie/teratome-ovarien), <https://www.deuxiemeavis.fr/pathologie/teratome-ovarien>, 2022, Revue par le Professeur Bruno Borghese
- (4) Lamblin, G., Gallice, C., Bournaud, C., Nadaud, B., Lebaill-Carval, K., & Chene, G. (2016). Goîtres ovariens bénins : à propos de 7 cas et analyse de la littérature. Gynécologie Obstétrique & Fertilité, 44(5),263-268. doi: <https://doi.org/10.1016/j.gyobfe.2016.02.009>
- (5) Zekri, J. M., Manifold, I. H., & Wadsley, J. C. (2006). Metastatic Struma Ovarii: Late Presentation, Unusual Features and Multiple Radioactive Iodine Treatments. Clinical Oncology, 18(10), 768–772. doi: <https://doi.org/10.1016/j.clon.2006.09.002>
- (6) Krichen Makni, S., Bahri, I., Ellouze, S., Mnif, H., Ayadi, L., Ghariani, M., Boudawara, T. (2005). Goitre ovarien malin. Journal de Gynécologie Obstétrique et Biologie de La Reproduction, 34(8), 815–818. doi: [https://doi.org/10.1016/s0368-2315\(05\)82960-6](https://doi.org/10.1016/s0368-2315(05)82960-6)
- (7) DeSimone, C. P., Lele, S. M., & Modesitt, S. C. (2003). Malignant struma ovarii: a case report and analysis of cases reported in the literature with focus on survival and ¹³¹I therapy. Gynecologic Oncology, 89(3), 543–548. doi: [https://doi.org/10.1016/s0090-8258\(03\)00141-0](https://doi.org/10.1016/s0090-8258(03)00141-0)
- (8) Boutaina Lachiri,& Zineb Benkerroum, Mohamed Allaoui, Zazi Abdelgheni, Khalid Guelzim, Jaouad Kouach, Driss Moussaoui Rahali, Mohamed Dehaynin; Goitre ovarien bénin: à propos d'un cas et revue de la littérature. Pan African Medical Journal. 2015; 21:271 doi: <https://doi.org/10.11604/pamj.2015.21.271.7209>
- (9) [Mandic A, Tesic M, Rajovic J, Vujkov T, Zivalijevic M, Mihajlovic O. Ovarian teratomas: Struma ovarii. Arch Oncol. 2001; 9\(3\):189-91](https://doi.org/10.1007/s12094-001-9189-1)
- (10) Slim, I., El Bez, I., Yeddes, I., El Ajmi, W., Letaief, B., Mhiri, A., & Ben Slimène, F. (2009). Trans-formation maligne d'un goitre ovarien. À propos d'une observation. Médecine Nucléaire, 33(10), 637–641. doi: <https://doi.org/10.1016/j.mednuc.2009.07.005>
- (11) Hatami M, Breining D, Owers RL, Del Priore G, Goldberg GL. Malignant struma ovarii: a case report and review of the literature. Gynecol Obstet Invest 2008;65:104–7. DOI: <https://doi.org/10.1159/000108654>
- (12) Makani S, Kim W, Gaba AR. Struma ovarii with a focus of papillary thyroid cancer: a case report and review of the literature. Gynecol Oncol 2004;94(3):835–9
- (13) Meriem Koual, Huyen-Thu Nguyen-Xuan, Jonas Deidier, Marie-Aude Le Frère-Belda, Anne-Sophie Bats, Goitre ovarien ou struma ovarii : une tumeur ovarienne rare à ne pas méconnaître, Gynécologie Obstétrique Fertilité & Sénologie, Volume 48, Issue 11, 2020, Pages 837-839, ISSN 2468-7189, <https://doi.org/10.1016/j.gofs.2020.05.008>.