

# Role of <sup>99m</sup>Tc-HMDP Bone Scintigraphy in the Management of Neurogenic Para-Osteo-Arthropathies (NAOP)

Sofia Chkikar<sup>1</sup>, Assia Seddouki<sup>1</sup>, Nadia Ismaili Alaoui<sup>1</sup>

<sup>1</sup>Department of Nuclear Medicine, Hassan II University Hospital Center, Fez, Morocco

Swiss Journal of Radiology and Nuclear Medicine - [www.sjoranm.com](http://www.sjoranm.com) - SJORANM GmbH - CH-3072 Ostermundigen bei Bern - Switzerland

## Abstract

Neurogenic para-osteo-arthropathies (NAOP) are characterized by ectopic juxta-articular peri- or para-osseous ossifications. Diagnosis of these conditions is often delayed. They are frequently associated with central neurological disorders and are rarely observed in cases of peripheral neuropathy. Bone scintigraphy is crucial for determining the maturity of the ossification, optimizing surgical interventions, and preventing recurrence.

**Keywords:** Neurogenic Para- Osteo- Arthropathies (NAOP), ectopic juxta-articular peri- or para-osseous ossifications, maturity of the ossification, Brooker's classification.

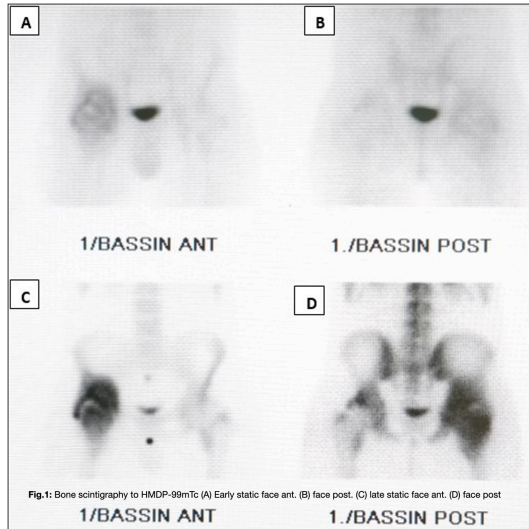


Fig.1: Bone scintigraphy to HMDP-99mTc (A) Early static face ant. (B) face post. (C) late static face ant. (D) face post

<sup>1</sup>Corresponding author: [Sofia.Chkikar](mailto:Sofia.Chkikar) - received: 22.04.2024 - peer reviewed, accepted and published: 04.05.2024

## Introduction

Neurogenic para-osteo-arthropathies (NAOPs), or heterotopic ossifications (HO), are defined as abnormal osteogenesis occurring in non-skeletal tissues, typically following an initial inflammatory process. These bone formations are not classified as neoplasms and can affect various types of soft tissue (1-4). They are commonly associated with central neurological disorders and are rare in cases of peripheral neuropathy (5-6). Typically located near limb joints, these ossifications can lead to mechanical complications such as compression of blood vessels or nerves, as well as joint stiffness, significantly impacting locomotor function (7). Diagnosis of heterotopic ossification relies on standard radiography, although abnormalities may not be evident until up to 4 weeks after disease onset. Bone scintigraphy is considered the preferred method for early detection and maturity assessment of heterotopic ossification (8). Additionally, complementary SPECT-CT scanning of suspected areas aids in lesion

localization, classification, and differential diagnosis from other pathologies (9-10).

The aim of this study is to elucidate the scintigraphic characteristics and demonstrate the significance of bone scintigraphy, as well as the additional benefits of SPECT-CT, in detecting heterotopic ossification.

## Materials and methods

We present five cases of NAOP diagnosed in 2021 at the Nuclear Medicine Department of Hassan II University Hospital in Fez. All patients underwent two-stage bone scintigraphy (BS) following the injection of 743 MBq (20 mCi) of hydroxymethylene diphosphonate (HMDP) labeled with Technetium 99m (Tc99m). The imaging protocol consisted of an early study (vascular and tissue phase) (Fig. 1) conducted between 0 and 10 minutes post-radiotracer injection, focusing on the region of interest and the adjacent joints, followed by a late study (bone phase) performed



2 to 3 hours later. The late study included whole-body scans anteriorly and posteriorly, supplemented by static images. Additionally, suspicious areas underwent SPECT-CT imaging, except in pediatric cases.

However, we encountered technical challenges during the scintigraphic examination in two patients. In one case, difficulties arose due to

imaging showed mature heterotopic ossification (OH).

#### Observation 4:

A 35 year old patient, who underwent surgery for secondary coxarthrosis two years ago, including a right total hip replacement (THR), presented with coxalgia and restricted joint mobility. Standard X-ray imaging revealed periarticular ossifi-

## Ectopic Ossification Following Total Hip Replacement Classification by Brooker et al.

Grade I	Ossifications around the hip
Grade II	Bone spurs appearing from the proximal femur and pelvis with a space $\geq 1$ cm between the two ends
Grade III	Bone spurs appearing from the proximal femur and pelvis with a space $\leq 1$ cm between the two ends
Grade IV	Ankylosis of the hip

**Tab. 1:** BROOKER, ANDREW F.; BOWERMAN, JACK W.; ROBINSON, ROBERT A.; RILEY, LEE H. JR.. Ectopic Ossification Following Total Hip Replacement: INCIDENCE AND A METHOD OF CLASSIFICATION. The Journal of Bone & Joint Surgery 55(8):p 1629-1632, December 1973.

joint flexion, which impeded the acquisition of a comprehensive whole-body scan and hindered visualization of all joints, particularly the elbows. In the other case, the patient's agitated neurological state posed challenges during the procedure.

## Results

### Observation 1:

A 16-year-old patient with a spinal cord injury, quadriplegic for 6 months, presented with right hip pain. Standard X-ray imaging revealed periarticular ossifications.

### Observation 2:

A 27-year-old patient experienced a head injury 6 months ago, leading to multifocal joint pain and restricted joint mobility. The bone scintigraphy (BS) revealed multiple areas of increased tracer uptake in the early stages, affecting the elbows, hips, and right knee. A supplementary SPECT-CT scan was conducted, revealing the presence of heterotopic ossifications associated with active multifocal NAOP (Fig. 2).


### Observation 3:

A 32-year-old patient with a history of hemorrhagic stroke presented with left elbow pain. Skeletal scintigraphy (SO) revealed delayed hyperfixation in the right elbow, and SPECT-CT

showed delayed hyperfixation, corresponding on SPECT and CT images to a mature bone bridge classified as grade III according to Brooker's classification.

## Discussion:

HO is a severe calcifying condition affecting periarticular tissues and areas, with the potential to involve all joints. According to Chalmers et al., the etiopathogenesis involves three essential factors for the formation of heterotopic ossification (HO): osteogenic precursor cells, inducing agents, and a permissive environment (12). Urist et al. discovered that demineralized bone matrix could induce ectopic bone formation by depositing small bone morphogenetic proteins. These proteins have the capability to transform mesenchymal cells of muscle origin into bone cells under favorable respiratory and nutritional conditions (13). They also suggest that these proteins are released by normal bone in response to venous stasis, inflammation, or connective tissue diseases associated with bone, situations often seen in immobilization and trauma (13). The initial stages of HO formation are characterized by the presence of infiltrate with edema and exudative cells, followed by fibroblastic proliferation and osteoid formation, which subsequently matures (14).

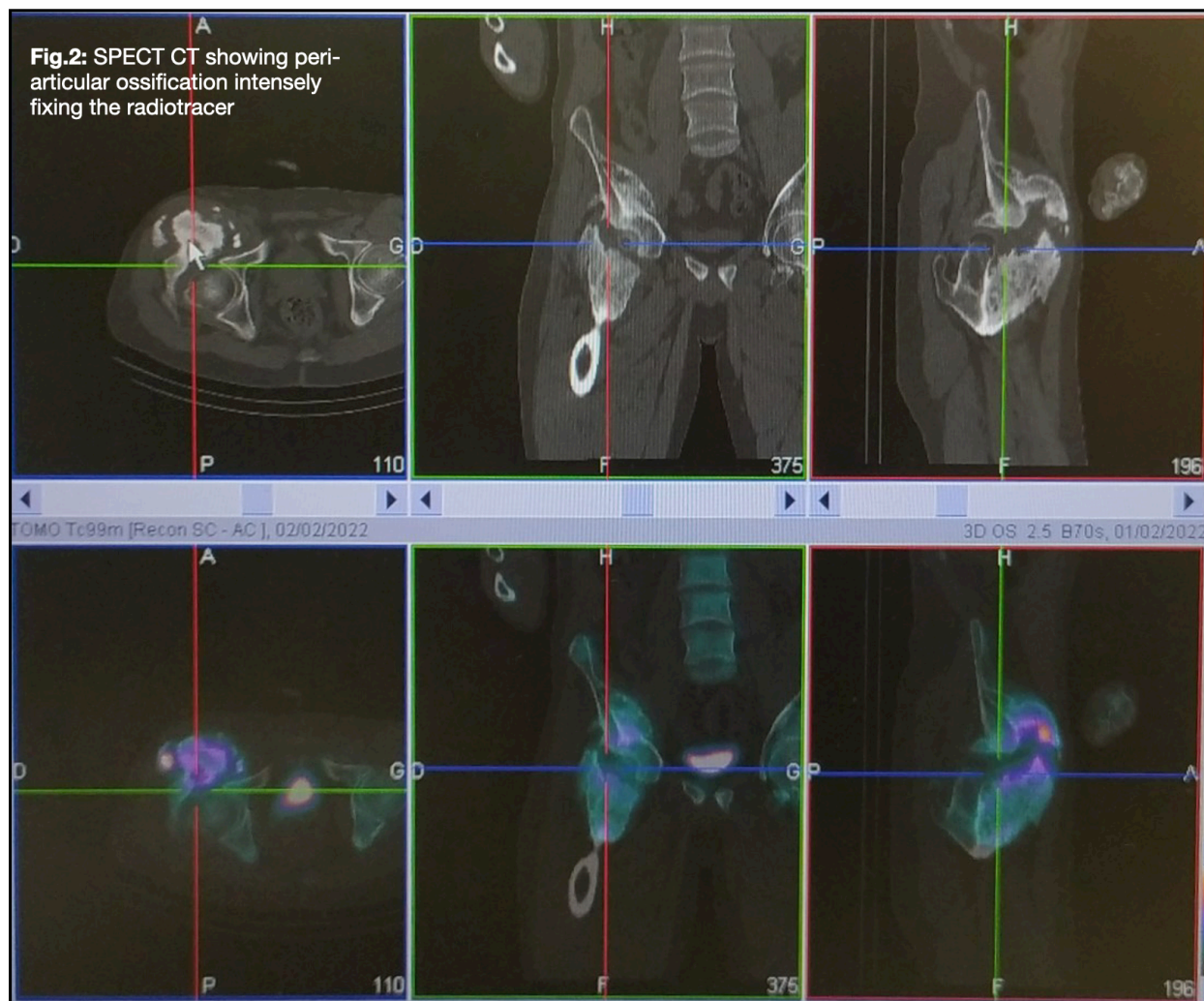


Clinical signs of heterotopic ossification (HO) may manifest between the third and twelfth weeks following musculoskeletal trauma, spinal cord injury, orthopedic surgery, prolonged intensive care stay (11), or other precipitating events (15, 16, 17). These signs typically progress through three stages: acute pseudo-inflammatory (lasting 4 to 5 weeks), chronic (lasting 4 to 6 months), and regressive with eventual symptom disappearance (1 to 2 years) (18).

The most commonly affected areas include the hips, followed by the knees, shoulders, elbows, and rarely the feet (15, 16, 17). The primary com-

disease and decrease as the ossifications mature (21). Unfortunately, alkaline phosphatase levels cannot reliably indicate the maturity or recurrence of HO, as they may remain within the normal range even in the presence of active HO (21). None of our patients underwent alkaline phosphatase testing for diagnostic purposes.

Standard radiography typically reveals circumferential ossifications with clear centers (22). However, it may only become positive 4 to 6 weeks after a positive bone scan (21-23). On computed tomography (CT), early non-mineralized lesions appear as poorly circumscribed soft



lications associated with HO are loss of joint mobility and function, leading to contractures and ankylosis, as well as other issues like peripheral nerve compression and pressure ulcers (15, 19, 20). In our patient cohort, the hip was the most frequently affected site, followed by the elbow, knee, and ankle.

HO is unrelated to any abnormalities in phosphocalcium metabolism. However, alkaline phosphatase levels may rise in the early stages of the

tissue hypodensities, which can pose challenges in the differential diagnosis with infectious and tumorous lesions, thereby limiting its specificity in the early stages. Subsequently, calcifications develop, and CT plays a pivotal role in delineating the extent of bone formation and guiding radiotherapy and surgical interventions (26). Magnetic resonance imaging (MRI) is utilized to detect contrast enhancement, indicative of residual activity (27).



Three-phase bone scintigraphy is the most sensitive imaging modality for the early detection of HO (5, 17, 24, 25). Vascular changes can typically be detected as early as 2.5 weeks after the event responsible for HO, whereas osteoblastic activity becomes evident approximately a week later, manifesting as extra-skeletal hyperfixations (2, 17). These scintigraphic abnormalities tend to diminish as the osteomas mature, with activity returning to normal levels around 6 to 12 months (28).

The scintigraphic appearance of heterotopic ossification (HO) lacks specificity and may resemble other pathologies, particularly infectious and tumorous conditions. Therefore, completing the evaluation with a SPECT-CT scan is advantageous, as it provides precise anatomical localization of HO and surpasses other imaging modalities in accuracy. Moreover, SPECT-CT facilitates the assessment of HO maturation before surgery to prevent recurrence and allows for the classification of hip disorders according to (Tab. 1) Brooker et al. (19, 29, 30). Among our three patients with hip involvement, one exhibited grade III HO, while the remaining two did not undergo SPECT-CT due to their agitated neurological state and young age.

### Conclusion:

Neurogenic para-osteo-arthropathy presents several diagnostic and therapeutic challenges. While the symptoms provide valuable indications, there is currently no biological test for definitive diagnosis of this condition. However, skeletal scintigraphy (SO) combined with SPECT-CT allows for early detection of heterotopic ossification (HO), assessment of its maturity, and classification according to Brooker's criteria, thereby guiding treatment decisions.

Correspondence to

[Sofia Chkikar](mailto:Sofia.Chkikar@chhassan2.ma)

Centre Hospitalier Universitaire Hassan II  
Fès, Morocco, Centre Hospitalier Hrazem  
BP:1835 Atlas, Fès, Avenue Hassan II  
Fes 30050, Marokko



### Conflict of interest:


The authors declare that there were no conflicts of interest within the meaning of the recommendations of the International Committee of Medical Journal Editors when the article was written.

### Disclaimer/Publisher's Note:

The statements, opinions and data contained in all publications are solely those of the individual author(s) and contributor(s) and not of Swiss J. Radiol. Nucl. Med. and/or the editor(s). Swiss J. Radiol. Nucl. Med. and/or the editor(s) disclaim responsibility for any injury to people or property resulting from any ideas, methods, instructions or products referred to in the content.

### References

- Wharton GW, Morgan TH. Ankylosis in the paralyzed patient. *J Bone Joint Surg Am.* 1970; 52(1): 105-12.
- Orzel JA, Rudd TG. Heterotopic bone formation: clinical, laboratory, and imaging correlation. *J Nucl Med.* 1985;26(2):125-32.
- Citak, Mustafa MD; Suero, Eduardo M. MD; Backhaus, Manuel MD; Aach, Mirko MD; Godry, Holger MD; Meindl, Renate MD; Schildhauer, Thomas A. MD. Risk Factors for Heterotopic Ossification in Patients With Spinal Cord Injury: A Case-Control Study of 264 Patients. *Spine* 37(23):p 1953-1957, November 01, 2012. | DOI: 10.1097/BRS.0b013e31825ee81b.
- Melo RM, Mendonça MQ, Mendonça ET, Mendonça EQ. Ossificação heterotópica em saco herniário incisional. *Rev Col Bras Cir.* 2012;39(2):151-4.
- Garland DE. A clinical perspective on common forms of acquired heterotopic ossification. *Clin Orthop Relat Res.* 1991;(263):13 -29.
- Coelho CV, Beraldo PS. Risk factors of heterotopic ossification in traumatic spinal cord injury. *Arq Neuropsiquiatr.* 2009;67(2B): 382-7.
- Pélissier J, Petiot S, Bénéaim C, Asencio G. Treatment of neurogenic para-osteo-arthropathies (POAN) in patients with cranio-encephalic trauma. *Ann Réadaptation Méd Phys* 2002 ; 45: 188-97.
- Shehab D, Elgazzar H, Collier B. Heterotopic ossification. *J Nucl Med.* 2002;43:346-53.
- Lima, MC, Passarell, MC, Dario V, Lebani BR, Silva Monteiro PHS. RamosCD: The use of SPECT/CT in



- the evaluation of heterotopic ossification in para/tetraplegics. [Acta Ortop Bras. 2014; 22:12-6.](#)
10. Lin Y, Lin WY, Kao CH, Shih C, Tsai SC. Easy interpretation of heterotopic ossification demonstrated on bone SPECT/CT. [Clin. Nucl. Med. 2014;39:62-3.](#)
  11. Shawgi M. Heterotopic ossification of the hips in a patient with Guillain-Barré syndrome demonstrated on SPECT/CT. [Clin Nucl Med. 2012; 37:e253-4.](#)
  12. Chalmers J, Gray DH, Rush J. Observations on the induction of bone in soft tissues. [J Bone Joint Surg Br. 1975;57:36-45.v](#)
  13. Urist MR, Nakagawa M, Nakata N, Nogami H. Experimental myositis ossificans: cartilage and bone formation in muscle in response to diffusible bone matrix derived morphogen. [Arch Pathol Lab Med. 1978;102:312-316.](#)
  14. Jensen LL, Halar E, Little J, Brooke MM. Neurogenic heterotopic ossification. [Am J Phys Med Rehabil. 1987;66:351-363.](#)
  15. Rossier AB, Bussat P, Infante F, et al. Current facts on para-osteoarthropathy (POA). [Paraplegia. 1973;11:36- 78.](#)
  16. Wharton GW, Morgan TH. Ankylosis in the paralyzed patient. [J Bone Joint Surg Am. 1970;52:105-112.](#)
  17. Freed JH, Hahn H, Menter R, Dillon T. The use of three-phase bone scan in the early diagnosis of heterotopic ossification (HO) and in the evaluation of Didronel therapy. [Paraplegia. 1982;20:208-216.](#)
  18. Moyen B, Chouteau J. Scintigraphie osseuse de appareil locomoteur. [Médecine Nucléaire, Imagerie Fonctionnelle et Métabolique 2003; 27 \(11\): 596-9.](#)
  19. Brooker AF, Bowerman JW, Robinson RA, Riley LH Jr. Ectopic ossification following total hip replacement: incidence and method of classification. [J Bone Joint Surg Am. 1973; 55: 1629-1632.](#)
  20. Sawyer JR, Myers MA, Rosier RN, Puzas JE. Heterotopic ossification: clinical and cellular aspects. [Calcif Tissue Int. 1991;49:208-215.](#)
  21. Orzel JA, Rudd TG. Heterotopic bone formation: clinical, laboratory and imaging correlation. [J Nucl Med. 1985;26:125-132.](#)
  22. Helms CA., Skeletal don't touch lesions. In: Brant WE, Helms CA; eds. [Fundamentals of Diagnostic Radiology. Baltimore, MD: Williams & Wilkins; 1994:963-975.](#)
  23. Mysiw, WJ; Tan, J; Jackson, RD. HETERO-TOPIC OSSIFICATION: The Utility of Osteo-calcin in Diagnosis and Management. [American Journal of Physical Medicine & Rehabilitation 72\(4\):p 184-187, August 1993.](#)
  24. Garland DE. A clinical perspective on common forms of acquired heterotopic ossification. [Clin Orthop. 1991;263:13-29.](#)
  25. Tyler JL, Derbekyan V, Lisbona R. Early diagnosis of myositis ossificans with Tc-99m diphosphonate imaging. [Clin Nucl Med. 1984;9:256-258.](#)
  26. Bossche L, Vanderstraeten G. Heterotopic ossification: a review. [J Rehabil Med. 2005;37: 129-36.](#)
  27. Haloua M, Houmada Y, Lamrani YA, et al. The neuropathic osteoarthropathy of the hip: About two cases. [La Tunisie Medicale. 2017 May;95\(5\):381-384. PMID: 29509223.](#)
  28. Tibone J, Sakimura I, Nickel VL, Hsu JD. Heterotopic ossification around the hip in spinal cord-injured patients: a long-term follow-up study. [J Bone Joint Surg Am. 1978; 60:769-775.](#)
  29. Ghanem, Mohammad A., Shuroouq Dannoon, and Abdelhamid H. Elgazzar. "The added value of SPECT-CT in the detection of heterotopic ossification on bone scintigraphy." [Skeletal Radiology 49 \(2020\): 291-298.](#)
  30. Lima MC, Passarelli MC, Dario V, Lebani BR, Silva Monteiro PHS, Ramos CD: The use of SPECT/CT in the evaluation of heterotopic ossification in para/tetraplegics. [Acta Ortop Bras. 2014;22:12-6.](#)