Ultrasound Assessment of Compression-Ischemic Neuropathy of the Infrapatellar Branch of the Saphenous Nerve in Patients with Grade II–III Knee Osteoarthritis

Evgeniy A. Andronnikov[1*], Rodion N. Drandrov[1], Alexey Yu. Eldyrev[1], Alexander V. Gogulin[1]

[1]Federal Center for Traumatology, Orthopedics and Arthroplasty, Cheboksary, Russia

Swiss Journal of Radiology and Nuclear Medicine - SJORANM GmbH - Rosenweg 3 - CH-6340 Baar - Switzerland

Abstract

Background/Objective. To perform an ultrasound (US) assessment of pathologically altered periarticular soft tissue structures in the medial compartments of the knee joint in patients with knee osteoarthritis (OA) and to evaluate the relationship between these changes and anterior medial knee pain.

Materials and Methods. A prospective, randomized, single-center study was conducted at the Federal Center for Traumatology, Orthopedics and Arthroplasty (Cheboksary, Russia) from 2021 to 2022, enrolling 82 patients. The main group (n=42) included patients with grade II–III OA, varus/valgus deformity, and anterior medial knee pain; the control group (n=40) comprised patients with grade 0–I OA without pain. All participants underwent physical examination (Tinel sign), US assessment of superior femoral ligament (SFL) protrusion and anteroposterior dimension of the interfascial space (APDIFS) in the infrapatellar branch projection, a 10-point numeric pain rating scale (NRS), and the Pain-Detect questionnaire.

Results. The two groups did not differ significantly in sex distribution and were characterized by a predominance of women (>98%, p=0.242). Patients in the main group were significantly older than those in the control group (p<0.001). SFL protrusion was significantly higher in the main group (7.6–13.8 mm vs. 2.5–6.8 mm, p<0.001), while APDIFS was significantly lower (0.2–0.8 mm vs. 1.2–2.1 mm, p<0.001). Based on clinical experience, we used an original practical classification of SFL protrusion on US: type 0 (<7.0 mm) – minimal or absent findings suggestive of CIN; type 1 (7.0–10 mm) – episodic symptoms; type 2 (>10 mm) – persistent clinical features possibly associated with CIN. Pronounced clinical signs suggestive of CIN were observed in 90.5% of patients with type 2 protrusion (n=38). In 23 patients with type 2 protrusion who did not respond to conservative treatment (54.8%), ultrasound-guided saphenous nerve blocks and subsequent radiofrequency ablation were performed for diagnostic purposes; pain regressed to 2–3 NRS points in 21 patients (91.3%). Fifteen patients (35.7%) underwent total knee arthroplasty with complete pain resolution. The positive outcome of the intervention showed no statistically significant difference between the two approaches (p=0.505).

Conclusion. Anterior medial knee pain in OA may have a neuropathic component possibly related to compression of the infrapatellar branch of the saphenous nerve due to SFL protrusion and interfascial space narrowing. Ultrasound can identify morphological changes associated with possible nerve compression rather than proving neuropathy, and may assist in selecting optimal diagnostic and therapeutic strategies.

Keywords: neuropathy; pain syndrome; knee joint; infrapatellar nerve; knee osteoarthritis

*Corresponding author: *Evgeniy A. Andronnikov. Submission:09.06.2026; Peer reviewed, accepted and published: 28.07.2026.*

Introduction

Osteoarthritis (OA) is a common joint disease affecting various age groups. According to the Global Burden of Disease Study 2021, OA affected 607 million people worldwide in 2021 (8.3% of the population), representing a 137% increase since 1990, and is a leading cause of disability in 10% of cases. The disease affects not only individuals over 65 years of age (about 73% of cases) but also younger people, especially after joint trauma, which underscores its significant medical and social importance [1].

It is well known that pain severity does not always correlate with the degree of pathological changes in the joint. Contemporary research confirms that structural alterations identified on radiography or MRI cannot reliably predict pain in patients with knee osteoarthritis [2]. Pain is the key symptom of osteoarthritis, substantially affecting quality of life and daily activities, which may lead to the development of pain-related behavior [2].

For a long time, pain in knee OA, particularly at advanced stages (II–III), was considered a consequence of exclusively degenerative changes. However, this model does not explain the lack of a direct relationship between pain level and the degree of structural changes, nor the presence of secondary hyperalgesia. The pathophysiology of OA pain is now understood to be complex

Open Access · CC BY 4.0 · © 2026 The Author(s) · Published by SJORANM GmbH, Switzerland

and often cannot be explained solely by radiological changes, with pain sensitization playing a key role in this discrepancy [3].

Physical examination of OA patients often reveals neuropathic sensations, such as hyperalgesia and allodynia, which suggest the potential involvement of neuropathic mechanisms in pain development. Contemporary evidence suggests that OA pain is not exclusively nociceptive but may involve neuropathic peripheral and central abnormalities, and that pain experience is often poorly correlated with structural modifications [4].

Current knowledge and our previous observations suggest that anterior medial knee pain in patients with knee osteoarthritis may be associated with compression-ischemic neuropathy, a variant of entrapment neuropathy. These observations are supported by clinical cases in which ultrasound examination revealed entrapment of the infrapatellar branch of the saphenous nerve at its passage through the sartorius muscle, which served as a possible cause of anterior medial knee pain, including in patients without prior surgical intervention [5, 6].

Compression-ischemic neuropathies (CIN) result from nerve injury in vulnerable anatomical regions. Entrapment neuropathies (EN), as a subtype of CIN, are characterized by nerve compression within a narrow anatomical tunnel or «trap» [7, 8]. CIN most often occur in areas where nerve trunks pass through canals, tunnels, and narrow intertissue spaces formed by ligaments, fasciae, tendons, muscles, and bones. Under the influence of various factors, acute or chronic mechanical irritation or compression of the nerve trunk can occur [5, 9].

During ultrasound examination of patients with entrapment neuropathies, an important task is to verify local pathological processes contributing to the tunnel conflict. To assess morphological changes in peripheral nerves, high-frequency ultrasound (7–18 MHz) is actively used [10].

The work by Mozolevsky and Barinov (2013) addressed general issues of pathogenesis, etiology, clinical manifestations, and treatment methods of tunnel syndromes [11]. However, it lacks data on direct compression of the peripheral nerve at the level of the medial knee compartment.

Published studies have described methods for investigating conditions that cause injury to the saphenous nerve and its infrapatellar branch. These conditions are not always related to trauma [5, 12].

To date, numerous scientific reports on various neuropathies have been published. In the study by Zharikova et al. (2020), infrapatellar neuropathy is considered a possible cause of knee pain, likely associated with compression of the saphenous nerve in the adductor canal [13]. However, that study does not present methods for instrumental diagnosis of nerve compression at the level of the medial knee compartment, nor the degree and parameters of compression.

Identifying the association between compression of the saphenous nerve and its infrapatellar branches with hyperalgesia in the anterior medial knee region is of great importance. Therefore, a relevant clinical task is the assessment of possible compression-ischemic neuropathy of the

infrapatellar branch of the saphenous nerve with findings suggestive of perineural changes in the surrounding soft tissues using ultrasound.

The space between the superficial fascia and the fascia lata at the knee level serves as a tunnel for the infrapatellar branch. Extraperineural changes in this area may impair nerve function and contribute to the development of neuropathic pain, which is consistent with a patent describing a method for selecting treatment for compression-ischemic neuropathy of the infrapatellar branch of the saphenous nerve in patients with knee osteoarthritis [6].

Thus, a pathogenetically grounded CIN of the infrapatellar branch emerges, providing the orthopaedic surgeon with valuable information to determine the patient's treatment strategy, which can be adapted according to the pathological changes in the periarticular soft tissue structures of the knee region identified by ultrasound imaging.

Aim of the Study

To perform an ultrasound (US) assessment of pathologically altered periarticular soft tissue structures in the medial compartments of the knee joint in patients with knee osteoarthritis (OA) and to evaluate the relationship between these changes and anterior medial knee pain.

Materials and Methods

A prospective, randomized, single-center study was conducted at the Federal Center for Traumatology, Orthopedics and Arthroplasty (Cheboksary, Russia) from 2021 to 2022, enrolling 82 patients.

Inclusion criteria: confirmed diagnosis of knee osteoarthritis, categorized according to the Kellgren–Lawrence classification; age over 18 years; patient consent to participate.

Group 1 (main group, n=42) included patients with grade II–III OA, varus/valgus deformity, and anterior medial knee pain.

Group 2 (control group, n=40) comprised patients with grade 0–I OA without pain.

The following methods and parameters were used:

- Clinical physical examination (tactile and pain sensitivity, Tinel test for tunnel syndrome);
- Knee radiography (limb axis assessment, varus/valgus angle measurement);
- Ultrasound (US) assessment of superior femoral ligament (SFL) protrusion and the anteroposterior dimension of the interfascial space (APDIFS) in the projection of the infrapatellar branch of the saphenous nerve at the joint line level near the medial collateral ligament;
- 10-point numeric pain rating scale (NRS);
- PainDetect questionnaire for neuropathic pain.

All US examinations were performed using Samsung X60 and Philips Sparq ultrasound systems with a 5–13 MHz linear high-density transducer. All examinations were performed by a single experienced musculoskeletal radiologist (R.N.D.) with 15 years of experience. The readers interpreting the examinations were blinded to clinical data.

Patients were examined in the supine position with the lower limb in slight external rotation. The probe was placed longitudinally on the medial aspect of the knee to visualize the SFL. SFL contour was assessed by measuring the maximum vertical distance from the line connecting the proximal and distal attachment points of the SFL to the highest point of its ridge. This distance (in mm) defined the degree of SFL protrusion.

We used our original practical classification of US changes in knee osteoarthritis, based on 10 years of clinical experience:

- **Type 0**: SFL protrusion up to 7.0 mm – most often associated with minimal or absent clinical manifestations suggestive of CIN (patients without pain);
- **Type 1**: SFL protrusion of 7.0–10 mm – accompanied by episodic and inconsistent clinical manifestations suggestive of CIN;
- **Type 2**: SFL protrusion ≥10 mm – characterized by pronounced, persistent, and long-lasting clinical manifestations suggestive of CIN of the infrapatellar branch.

A protrusion >10.0 mm was considered highly suggestive of CIN of the infrapatellar branch. The threshold values of 7 mm and 10 mm were derived empirically from clinical observations and are preliminary; they require validation in independent cohorts.

Figure 1 (A, B) shows the US image of SFL protrusion (height indicated by arrow SD) with marked narrowing of the interfascial space (APDIFS arrow) – in the infrapatellar branch projection, the nerve is not visible due to severe narrowing of the interfascial space.

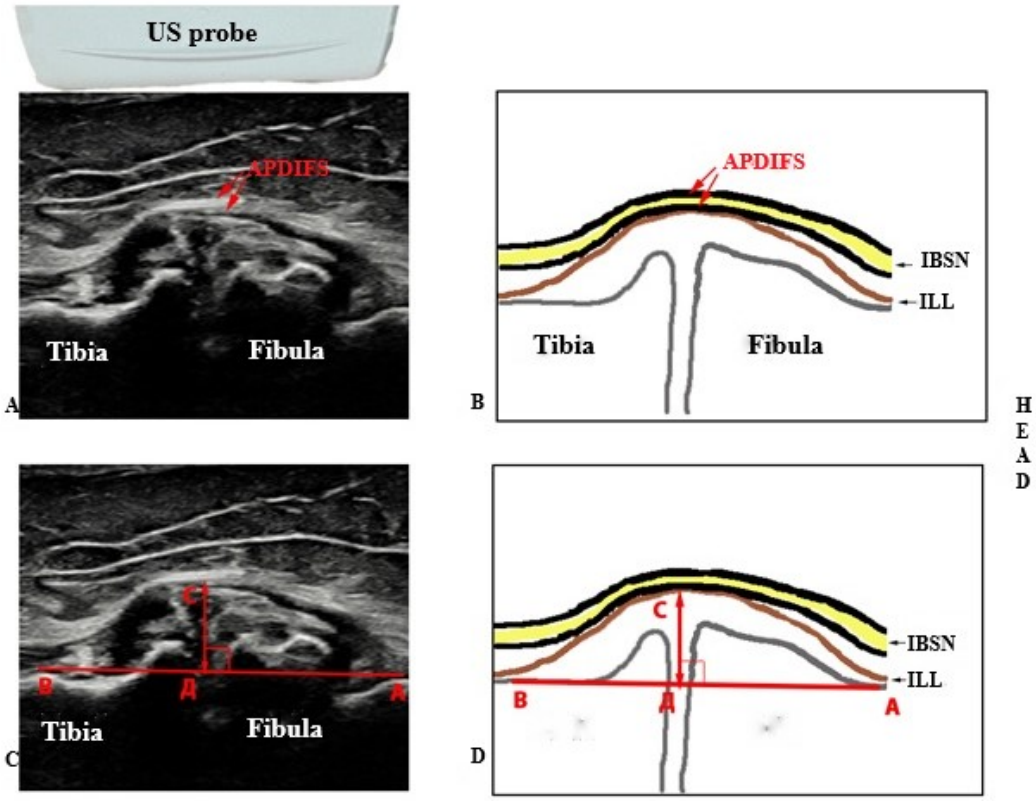

Fig. 1. Schematic representation of SFL protrusion at the joint line level: BK – medial condyle of femur with osteophyte; BBK – medial condyle of tibia with osteophyte; APDIFS – interfascial space with compressed infrapatellar branch at the level of maximal SFL protrusion; IPN – infrapatellar branch of the saphenous nerve

In the same projection, the infrapatellar branch within the APDIFS at the level of maximal SFL protrusion was identified and assessed. The distance between the fascial layers (APDIFS, measured in mm) served as an indicator of the degree of nerve compression. When the distance was <0.8 mm, it was considered an additional possible sign of CIN.

Figure 2 presents the normal US anatomy of the infrapatellar branch in the transverse scanning plane (nerve thickness 1.5 mm, APDIFS 2.1 mm).

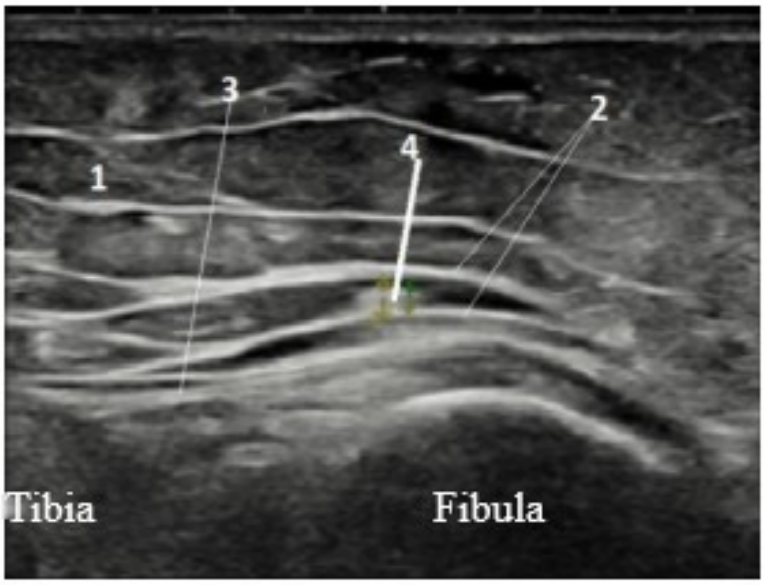

Fig. 2. Schematic representation of uncompressed infrapatellar branch within an unchanged interfascial space: BK – medial condyle of femur; BBK – medial condyle of tibia; 1 – subcutaneous adipose tissue; 2 – interfascial space; 3 – unchanged SFL; 4 – uncompressed infrapatellar branch

Figure 3 also schematically shows an uncompressed infrapatellar branch within an unchanged interfascial space (same labels as in Fig. 2).

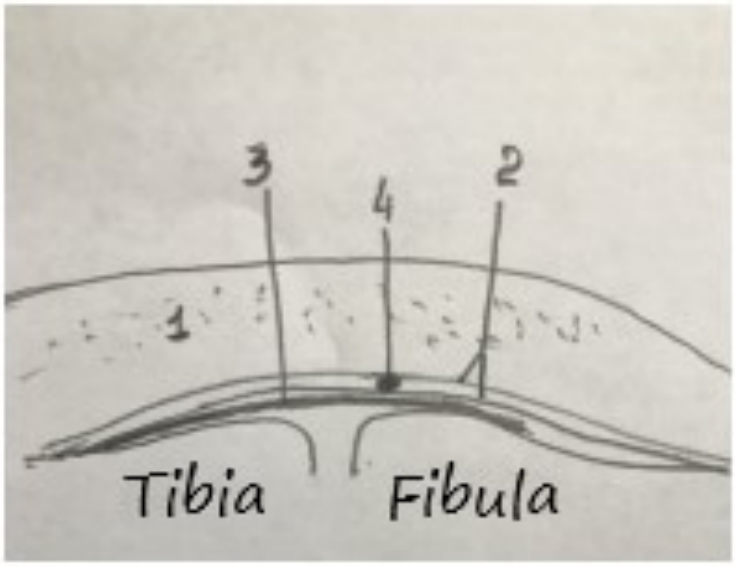

Fig. 3. Schematic representation of uncompressed infrapatellar branch within an unchanged interfascial space (labels as in Fig. 2)

Statistical analysis was performed using MedCalc and GraphPad software. Normality of distribution of continuous variables was assessed using the Kolmogorov–Smirnov and Shapiro–Wilk tests. For variables following a normal distribution, data were expressed as mean and standard deviation; for non-normally distributed variables, data were expressed as median and interquartile range Me [Q1–Q3]; in both cases, 95% confidence intervals were applied. For

categorical variables, intergroup significance was assessed using the chi-square test or Fisher's exact test. Correlation between SFL protrusion and clinical parameters was assessed using Spearman's rank correlation coefficient. Multivariable logistic regression was performed to identify independent predictors of CIN-suggestive findings. Differences were considered statistically significant at $p < 0.05$.

Results

The two groups did not differ significantly in sex distribution and were characterized by a predominance of women (>98%): n=39 in Group 1 versus n=40 in Group 2 (p=0.242). Regarding age, patients in the main group (Group 1) were significantly older than those in the control group (Group 2) (p<0.001).

Depending on the severity of anterior medial knee pain, different degrees of SFL protrusion and APDIFS values were visualized (Table 1).

Table 1

Degree of SFL protrusion and APDIFS values, 95% CI

Group/Sign	Age, years	SFL protrusion, mm	APDIFS, mm	PainDetect score, points	NRS score, points
Group 1, n=42 Me [Q1–Q3] min–max	60.5 [58.8; 62.2] 52–72	13.4 [12.9; 13.9] 7.6–13.8	0.3 [0.3; 0.3] 0.2–0.8	26.0 [25.1; 26.9] 19–31	7.0 [6.8; 7.2] 6–8
Group 2, n=40 Me [Q1–Q3] min–max	44.5 [43.6; 45.4] 35–48	4.7 [4.3; 4.5] 2.5–6.8	1.8 [1.7; 1.9] 1.2–2.1	0.0 [0.0; 0.0] 0–4	0.0 [0.0; 0.0] 0–1
p	<0.001	<0.001	<0.001	<0.001	<0.001

SFL protrusion height is a parameter measurable with mid-range ultrasound equipment and may serve as the primary preliminary screening characteristic for a possible association of pain with CIN of the infrapatellar branch. Measurement of APDIFS narrowing is more challenging in routine practice and depends on the availability of high-end equipment.

Analysis of patient complaints, NRS, and PainDetect results showed that when SFL protrusion exceeds 10.0 mm, clinical manifestations suggestive of CIN of the infrapatellar branch are pronounced, persistent, and long-lasting, while the effectiveness of standard conservative treatment is relatively low.

Pronounced clinical features consistent with CIN were observed in 90.5% of patients with type 2 protrusion (n=38), whereas in 9.5% of patients with type 1 protrusion (n=4), they were moderate.

Correlation analysis revealed a significant positive correlation between SFL protrusion and PainDetect score (Spearman's $r = 0.82$, $p<0.001$) and NRS score ($r = 0.79$, $p<0.001$), and a negative correlation between SFL protrusion and APDIFS ($r = –0.85$, $p<0.001$). Multivariable logistic regression identified SFL protrusion (OR = 1.45, 95% CI: 1.18–1.79, p<0.001) and APDIFS (OR = 0.12, 95% CI: 0.04–0.35, p<0.001) as independent predictors of CIN-suggestive findings.

The proposed method provided additional opportunities for determining and adjusting the management strategy for patients at the outpatient stage. In 23 patients with type 2 protrusion who did not respond to conservative treatment and had contraindications to arthroplasty, interventional methods (targeted extraperineural block and radiofrequency ablation under ultrasound guidance of the saphenous nerve) were applied for diagnostic purposes, with preliminary successful pain relief of the infrapatellar branch: as a result, in 21 of the 23 patients, pain regressed preliminarily to 2–3 points on the NRS, which was suggestive of a neuropathic component of the pain. The remaining 15 patients underwent total knee arthroplasty, with complete pain regression at the final follow-up (3 months postoperatively). The positive outcome of the intervention showed no statistically significant difference between the groups (p=0.505), possibly due to insufficient statistical power. The therapeutic response to nerve block should be interpreted as an exploratory observation rather than definitive proof of neuropathy.

Clinical case 1. Patient M., 68 years old, with medial right-sided grade III knee osteoarthritis. She complained of constant knee pain, predominantly in the anterior medial region. Physical examination revealed a positive Tinel sign; NRS pain score was 8–9 points; PainDetect score was 20 points. Radiography showed medial grade III knee osteoarthritis, genu varum. Knee ultrasound: joint surface deformation with cartilage degeneration and signs of medial meniscus lysis; SFL protrusion 12.0 mm, APDIFS 0.2 mm. The patient was classified as type 2 compression degree. Under ultrasound guidance, a selective extraperineural saphenous nerve block was performed for diagnostic purposes [6], with injection of 5 mL of 0.5% ropivacaine and 8 mg of dexamethasone. Five minutes after the injection, pain completely disappeared, suggesting a possible neuropathic component. One month later, the patient underwent total knee arthroplasty. Three months after surgery, pain was 1–2 points, with no local pain, and the patient was satisfied.

Clinical case 2. Patient P., 56 years old, presented with intermittent pain along the medial aspect of the knee for approximately 1 year. Radiography revealed medial grade I–II knee osteoarthritis, genu varum. Moderate pain on deep palpation of the medial knee region was noted, particularly in the pes anserinus area. NRS pain score was 3–4 points; Tinel sign in the medial knee region was equivocal; PainDetect score was 12 points. Knee ultrasound showed moderate joint surface deformation with cartilage and meniscal degeneration; SFL protrusion 8 mm; APDIFS 0.8 mm. The patient was assigned to type 0–1 compression degree. A 10-day rehabilitation course (anti-inflammatory therapy and physiotherapy) was prescribed. Positive dynamics were observed: NRS pain score decreased to 0–1 points, and pain resolved.

Study Limitations

No electromyography, nerve conduction studies, MR neurography, surgical confirmation, or histopathology were available to confirm the diagnosis of neuropathy. The threshold values of 7 mm and 10 mm for SFL protrusion were derived empirically and are preliminary; they require validation in independent cohorts. We acknowledge that the control groups differed in terms of OA severity and pain characteristics, which represents a potential confounding factor. To address this, future studies should compare patients with grade II–III OA with and without neuropathic

pain. The study was not registered in ClinicalTrials.gov, and no inter-server or intra-server agreements were calculated; however, the source data are available upon request. The therapeutic response to nerve block and radiofrequency ablation should be interpreted as exploratory findings rather than definitive proof of neuropathy. Interobserver and intraobserver agreement were not formally assessed because all US examinations were performed by a single experienced examiner.

Discussion

The present study demonstrates that ultrasound assessment of SFL protrusion and APDIFS may identify morphological changes associated with possible compression of the infrapatellar branch of the saphenous nerve in patients with knee osteoarthritis and anterior medial knee pain. The significant differences in SFL protrusion and APDIFS between the main and control groups ($p<0.001$) suggest that these parameters may be useful in identifying patients with a potential neuropathic component to their pain. The strong correlation between SFL protrusion and both PainDetect and NRS scores ($r = 0.82$ and 0.79, respectively) further supports this association.

These findings are consistent with recent international literature. Miyata et al. (2025) described a case of infrapatellar branch entrapment at the sartorius muscle penetration site, where ultrasound-guided manual therapy provided symptom relief [5]. Similarly, Drăghici et al. (2024) emphasized that entrapment neuropathies of the lower extremity, while rare, should be considered in patients with atypical pain patterns and no clear structural explanation [7]. The anatomical studies by Ferre-Martinez et al. (2023) and Kowalska (2014) have highlighted the importance of high-frequency ultrasound in identifying nerve entrapment at specific anatomical locations [9, 10].

The proposed ultrasound-based classification (types 0–2) offers a practical framework for stratifying patients according to the severity of morphological changes and associated clinical features. Type 2 protrusion (≥10 mm) was associated with persistent, severe symptoms in 90.5% of cases, suggesting that this threshold may identify patients most likely to benefit from targeted interventions. However, the preliminary nature of these thresholds must be emphasized, and validation in larger, independent cohorts is necessary before they can be recommended for routine clinical use.

The exploratory use of ultrasound-guided nerve blocks and radiofrequency ablation in patients with type 2 protrusion provided additional support for the possible neuropathic origin of pain, with 91.3% of treated patients experiencing significant pain reduction. However, these findings should be interpreted cautiously, as they were obtained in a small, selected subgroup and lack a control group. The lack of a statistically significant difference between the block and arthroplasty groups ($p=0.505$) may be due to insufficient statistical power and does not imply equivalence of the two approaches.

Several limitations of this study should be acknowledged. First, the absence of electrophysiological confirmation (EMG, nerve conduction studies) and MR neurography limits the ability to definitively confirm the diagnosis of neuropathy. Second, the control group differed

not only in pain status but also in OA severity, which may have introduced confounding. Third, the threshold values for SFL protrusion were derived empirically from clinical experience and require external validation. Fourth, the study was not registered in a clinical trials registry, and no interobserver or intraobserver agreement was assessed due to the single-examiner design. Finally, the therapeutic interventions described (nerve blocks and radiofrequency ablation) were applied in a small subgroup and should be considered exploratory rather than confirmatory.

Future studies should include patients with grade II–III OA without neuropathic pain to better isolate the effect of nerve compression. Validation of the proposed ultrasound classification using independent neurological reference standards, such as EMG and MR neurography, is essential. Correlation with surgical findings would further strengthen the clinical utility of this approach.

Conclusions

The findings of this study suggest that anterior medial knee pain in patients with knee osteoarthritis may have a neuropathic component possibly related to compression of the infrapatellar branch of the saphenous nerve, caused by SFL protrusion and narrowing of the interfascial space. Ultrasound can identify morphological changes associated with possible nerve compression, including significant narrowing of the interfascial space due to deformation of the medial knee compartments and SFL protrusion. However, ultrasound findings represent morphological correlates rather than definitive proof of neuropathy. These findings may help orthopaedic surgeons broaden the clinical interpretation of patient complaints during the initial examination and assist in selecting appropriate diagnostic and therapeutic strategies. Further validation studies using independent neurological standards, such as EMG and MR neurography, are needed before this approach can be recommended for routine clinical use.

References

1. Global Burden of Disease 2021 Osteoarthritis Collaborators. Global, regional, and national burden of osteoarthritis, 1990–2020 and projections to 2050: a systematic analysis for the Global Burden of Disease Study 2021. Lancet Rheumatol. 2023;5(9):e508-e522. DOI: https://doi.org/10.1016/S2665-9913(23)00163-7
2. The Discordance Between Pain and Imaging in Knee Osteoarthritis. J Arthroplasty. 2025;40(8):1992-1999.e1. DOI: https://doi.org/10.1016/j.arth.2025.01.050
3. Ohashi Y, Uchida K, Fukushima K, Inoue G, Takaso M. Mechanisms of Peripheral and Central Sensitization in Osteoarthritis Pain. Cureus. 2023;15(2):e35331. DOI: https://doi.org/10.7759/cureus.35331
4. Perrot S. Pain in osteoarthritis from a symptom to a disease. Best Pract Res Clin Rheumatol. 2023;37(1):101839. DOI: https://doi.org/10.1016/j.berh.2023.101839
5. Miyata T, Kawabata M, Watanabe D, et al. Ultrasound-Guided Manual Therapy for the Infrapatellar Branch of the Saphenous Nerve Entrapment Presenting as Anterior Knee Pain: A Case Report. Cureus. 2025;17(9):e93051. DOI: https://doi.org/10.7759/cureus.93051
6. Drandrov RN, Eldyrev AYu, Nikolaev NS, Kuzmina VA, Andronnikov EA. Method of nerve block with ultrasound navigation for the treatment of pain syndrome in the anterior-medial parts of the knee joint. Russian Federation patent RU 2720157 C1. 2020 Apr 24. (In Russian)
7. Drăghici NC, Bolchis R, Popa LL, Văcăraș V, Iluț S, Bashimov A, Domnița DM, Dragoș HM, Vlad I, Mureșanu DF. Rare entrapment neuropathies of the lower extremity: A narrative review. Medicine (Baltimore). 2024;103(35):e39486. DOI: https://doi.org/10.1097/MD.0000000000039486
8. Zharikova AV, Krivoshey OA, Tsukanova SA. Tunnel neuropathies of the pelvic girdle and lower extremities: practical guide for physicians. Gomel: Republican Scientific and Practical Center for Radiation Medicine and Human Ecology; 2020. (In Russian)

9. Ferre-Martinez A, Miguel-Pérez M, Möller I, Ortiz-Miguel S, Pérez-Bellmunt A, Ruiz N, Sanjuan X, Agullo J, Ortiz-Sagristà J, Martinoli C. Possible Points of Ulnar Nerve Entrapment in the Arm and Forearm: An Ultrasound, Anatomical, and Histological Study. Diagnostics (Basel). 2023;13(7):1332. DOI: https://doi.org/10.3390/diagnostics13071332
10. Kowalska B. Assessment of the utility of ultrasonography with high-frequency transducers in the diagnosis of entrapment neuropathies. J Ultrason. 2014;14(59):371-392. DOI: https://doi.org/10.15557/JoU.2014.0039
11. Mozolevsky YuV, Barinov AN. Complex treatment of tunnel neuropathies of the lower extremities. Neurology, Neuropsychiatry, Psychosomatics. 2013;4:10-21. (In Russian)
12. Drandrov RN, Nikolaev NS, Eldyrev AYu, Andronnikov EA, Kuksova VA. Method for selecting a treatment for compression-ischemic neuropathy of the infrapatellar branch of the saphenous nerve in patients with knee osteoarthritis. Russian Federation patent RU 2799913 C1. 2023 Jul 13. (In Russian)
13. Lyalina VV, Skripnichenko EA, Borisovskaya SV, et al. Neuropathy of the infrapatellar nerve as a cause of chronic pain in the knee joint. Therapy. 2023;9(5(67)):148-155. DOI: https://doi.org/10.18565/therapy.2023.5.148-155 (In Russian)

Authors' Contributions

Rodion N. Drandrov – Physician of Ultrasound Diagnostics, Federal Center for Traumatology, Orthopedics and Arthroplasty, Cheboksary, Russia; ORCID: 0000-0002-7595-9932; e-mail: rdrandrov@mail.ru

Alexey Yu. Eldyrev – Anesthesiologist-Intensivist, Federal Center for Traumatology, Orthopedics and Arthroplasty, Cheboksary, Russia; ORCID: 0009-0004-0054-6932; e-mail: lexito@bk.ru

Evgeniy A. Andronnikov – Head of the Radiology Department, Federal Center for Traumatology, Orthopedics and Arthroplasty, Cheboksary, Russia; ORCID: 0000-0002-3151-4368; e-mail: andronnikovevgenij@mail.ru

Alexander V. Gogulin – Orthopaedic Surgeon, Outpatient Department, Federal Center for Traumatology, Orthopedics and Arthroplasty, Cheboksary, Russia; ORCID: 0000-0002-3576-8736; e-mail: natalia240385@mail.ru

Correspondence to:

Evgeniy A. Andronnikov
Head of the Radiology Department
Federal Center for Traumatology, Orthopedics and Arthroplasty
Cheboksary
Russia
ORCID: 0000-0002-3151-4368
e-mail: andronnikovevgenij@mail.ru

Declarations

Ethics and consent: The study was approved by the relevant institutional ethics committee. Patient consent to participate was obtained.

Conflict of interest: The authors declare that there are no conflicts of interest.

Funding: This research received no external funding.

Data availability: The manuscript reports that source data are available upon request.

Disclaimer/Publisher's Note

The statements, opinions and data contained in all publications are solely those of the individual author(s) and contributor(s) and not of Swiss J. Radiol. Nucl. Med. and/or the editor(s). Swiss J. Radiol. Nucl. Med. and/or the editor(s) disclaim responsibility for any injury to people or property resulting from any ideas, methods, instructions or products referred to in the content.

License Policy

This work is licensed under a Creative Commons Attribution 4.0 International License. This license requires that reusers give credit to the creator. It allows reusers to distribute, remix, adapt, and build upon the material in any medium or format, even for commercial purposes.