# Transverse Testicular Ectopia Presenting as Primary Infertility in Adulthood: A Case Report

Arshed Hussain Parry · Shabir Ahmad Bhat · Sabeeha Gul · Mohmed Imran Wagay · Obaid Ashraf

Department of Radiodiagnosis and Imaging, Government Medical College, Srinagar, Jammu & Kashmir, India

Received: 27 January 2026 · Published: 26 February 2026

## Abstract

Transverse testicular ectopia is a congenital anomaly in which both testes are located on the same side. A 35-year-old man presented with primary infertility and azoospermia. The scrotum was empty, and neither testis was palpable in the scrotum or inguinal canals. Ultrasonography located both testes in the right iliac fossa in relation to the external iliac vessels. MRI corroborated their location and anatomical relationships. These findings supported an imaging diagnosis of transverse testicular ectopia with bilateral intra-abdominal testes. This case illustrates the role of ultrasound and MRI in localizing ectopic testes in an adult presenting with infertility.

Keywords: Transverse testicular ectopia, undescended testes, infertility, azoospermia.

## Background

Transverse testicular ectopia (TTE) is also known as crossed testicular ectopia. It is usually recognized in childhood, often in association with an inguinal hernia or other genitourinary anomalies. Associated findings described in the literature include persistent Müllerian duct structures and hypospadias [1,2,3,4,5].

## Correspondence

Arshed Hussain Parry · Department of Radiodiagnosis and Imaging, Government Medical College, Srinagar, Jammu & Kashmir, India

## Author Identifiers

Arshed Hussain Parry: https://orcid.org/0000-0001-5079-3430

Sabeeha Gul: https://orcid.org/0009-0004-0308-565X

Mohmed Imran Wagay: https://orcid.org/0009-0002-8468-4149


Open Access · CC BY 4.0 · © 2026 The Author(s) · Published by SJORANM GmbH, Switzerland
ISSN 2813-7221 · Swiss J. Radiol. Nucl. Med. 2026 28(1):28-32 · DOI 10.59667/sjoranm.v28i1.26

## Case Presentation

A 35-year-old man presented with primary infertility. He had been married for three years and reported no prior surgery or trauma. The general examination was unremarkable. The scrotum was empty, and neither testis was palpable in the scrotum or inguinal canals. There was no clinical evidence of inguinal hernia (Figure 1).

Semen analysis showed azoospermia. Serum testosterone was 7.74 ng/mL (reported reference range 2.49–8.36 ng/mL). The blood count and liver and kidney function tests were reported as within normal limits.



Figure 1. Clinical photograph showing an empty scrotum.

Ultrasonography localized both testes in the right iliac fossa, one anteromedial and the other anterolateral to the external iliac vessels. The reported testicular volumes were 5.5 and 6.6 mL. Both had normal echotexture, with no focal lesion identified (Figure 2).

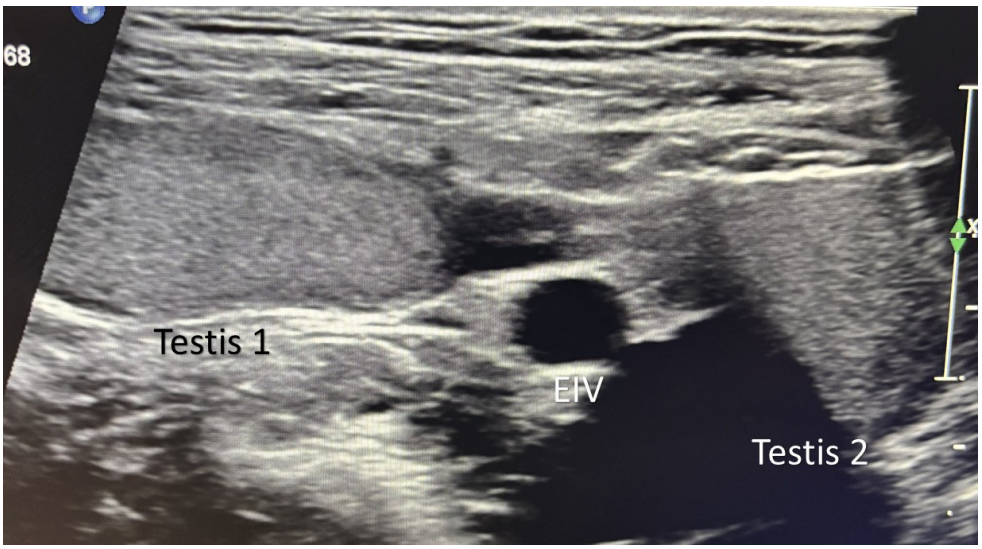


Figure 2. Ultrasound of the right iliac fossa shows both testes (arrows) in relation to the external iliac vessels.


Open Access · CC BY 4.0 · © 2026 The Author(s) · Published by SJORANM GmbH, Switzerland
ISSN 2813-7221 · Swiss J. Radiol. Nucl. Med. 2026 28(1):28-32 · DOI 10.59667/sjoranm.v28i1.26

## MRI and Surgical Planning

MRI corroborated the location of both testes and their relationship to the external iliac vessels (Figures 3 and 4). The bladder, prostate, seminal vesicles and kidneys were reported as normal. No persistent Müllerian duct structures were identified.

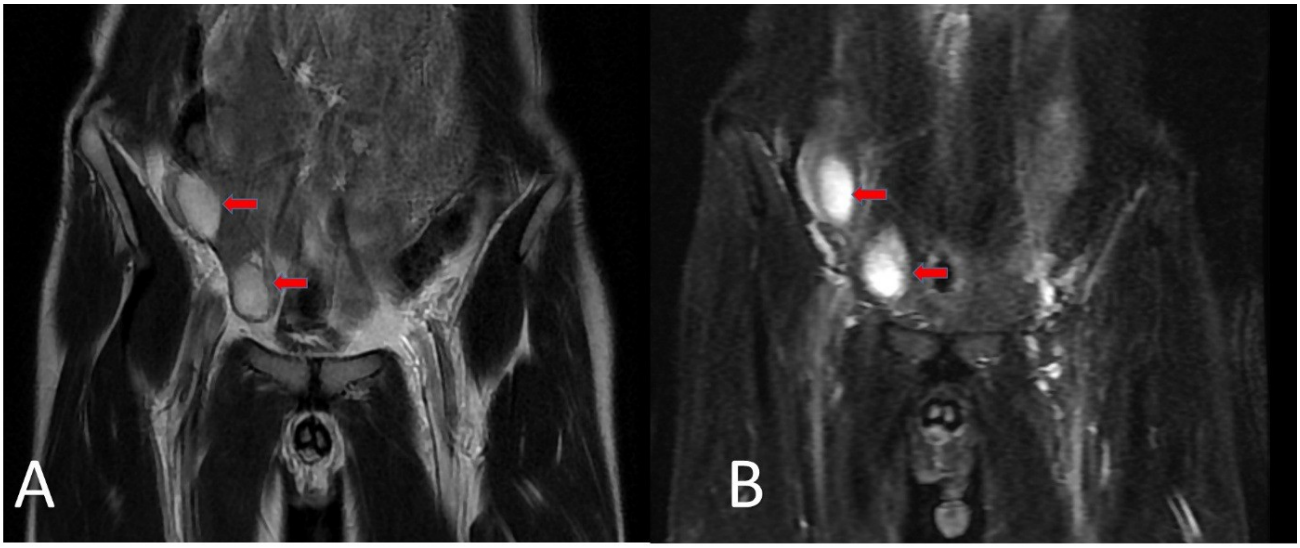


Figure 3. Coronal T2-weighted (A) and STIR (B) images show both testes in the right iliac fossa (arrows).

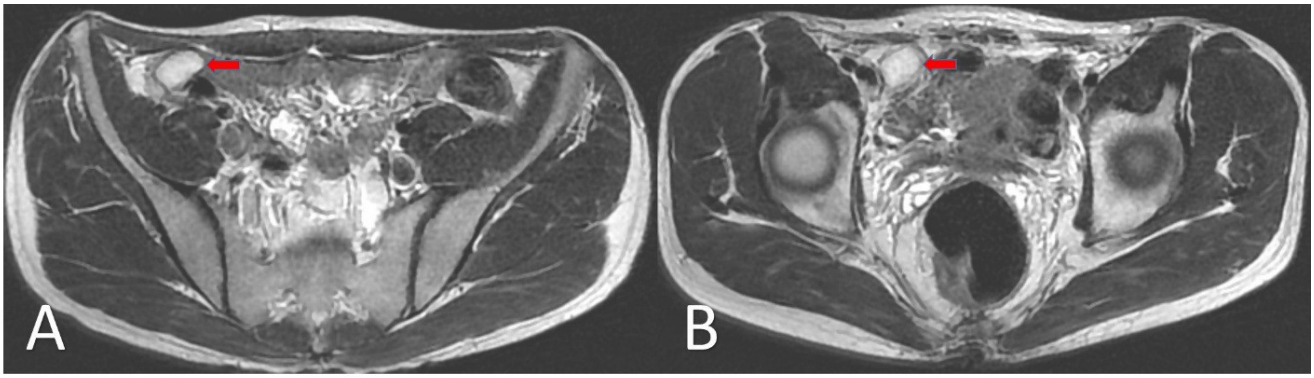


Figure 4. Axial T2-weighted images show both testes in relation to the right external iliac vessels (arrows).

The imaging findings supported a diagnosis of transverse testicular ectopia with both testes in the right iliac fossa. Surgery was planned.


Open Access · CC BY 4.0 · © 2026 The Author(s) · Published by SJORANM GmbH, Switzerland
ISSN 2813-7221 · Swiss J. Radiol. Nucl. Med. 2026 28(1):28-32 · DOI 10.59667/sjoranm.v28i1.26

## Discussion

In TTE, one testis crosses the midline during descent. Both testes may be found in the same inguinal canal, hemiscrotum or iliac fossa. The developmental mechanism remains uncertain. Proposed explanations include abnormal duct development or gubernacular attachment and altered descent associated with persistent Müllerian duct structures [5,6,8,9]. The published classification distinguishes presentations associated with inguinal hernia, persistent Müllerian duct structures and other genitourinary anomalies [4,5].

Ultrasonography identified both testes in the right iliac fossa. MRI corroborated their position and delineated their relationship to the external iliac vessels. In this case, the two modalities provided complementary anatomical information for surgical planning.

In this case, examination did not indicate an inguinal hernia, and imaging did not identify persistent Müllerian duct structures. Published management options include orchidopexy using transseptal or transperitoneal approaches, with repair of an associated hernia when present. The choice of approach depends on the anatomy [9,10,11].

## Conclusion

This case illustrates presentation of transverse testicular ectopia in adulthood with primary infertility and the complementary contribution of ultrasound and MRI to preoperative localization.

## Declarations

The authors report written informed consent for publication and preservation of anonymity. The work was conducted in accordance with the Declaration of Helsinki and applicable standards. All authors contributed to conception and drafting or critical revision, approved the final version and agreed to be accountable for the work.

Competing interests: None declared. Funding: No funding was required for this work.


Open Access · CC BY 4.0 · © 2026 The Author(s) · Published by SJORANM GmbH, Switzerland
ISSN 2813-7221 · Swiss J. Radiol. Nucl. Med. 2026 28(1):28-32 · DOI 10.59667/sjoranm.v28i1.26

## References

1. Moslemi MK, Ebadzadeh MR, Al-Mousawi S. Transverse testicular ectopia, a case report and review of literature. GMS German Medical Science. 2011 Jul 7;9:Doc15. https://doi.org/10.3205/000138

2. Naji H, Peristeris A, Stenman J, Svensson JF, Wester T. Transverse testicular ectopia: three additional cases and a review of the literature. Pediatric surgery international. 2012 Jul;28(7):703-6. https://doi.org/10.1007/s00383-012-3105-7

3. Raj V, Redkar R, Krishna S, Tewari S. Rare case of transverse testicular ectopia–case report and review of literature. International journal of surgery case reports. 2017 Jan 1;41:407-10. https://doi.org/10.1016/j.ijscr.2017.09.032

4. Naouar S, Maazoun K, Sahnoun L, Jouini R, Ksia A, Elezzi O, Krichene I, Mekki M, Belghith M, Nouri A. Transverse testicular ectopia: a three-case report and review of the literature. Urology. 2008 Jun 1;71(6):1070-3. https://doi.org/10.1016/j.urology.2007.11.133

5. Zhou G, Yin J, Jiang M, Yang Z, Li S. Clinical characteristics, ultrasonographic findings, and treatment of pediatric transverse testicular ectopia: a 10-year retrospective review. Urology. 2021 Aug 1;154:249-54. https://doi.org/10.1016/j.urology.2021.01.006

6. Abokrecha A, Sayed AG, Syed H, Joueidi F, Alzahrani L. Transverse testicular ectopia: two case reports and literature review. International Journal of Surgery Case Reports. 2023 Oct 1;111:108807. https://doi.org/10.1016/j.ijscr.2023.108807

7. Abdullayev T, Korkmaz M. Transvers testicular ectopia: a case report and literature review. International Journal of Surgery Case Reports. 2019 Jan 1;65:361-4. https://doi.org/10.1016/j.ijscr.2019.11.007

8. Sipani M, Bhat A, Prabhakar G. Transverse testicular ectopia: A report of five cases and review of literature. Journal of Indian Association of Pediatric Surgeons. 2020 Nov 1;25(6):404-7. https://doi.org/10.4103/jiaps.JIAPS_17_20

9. Punwani VV, Wong JS, Lai CY, Chia JC, Hutson JM. Testicular ectopia: Why does it happen and what do we do?. Journal of pediatric surgery. 2017 Nov 1;52(11):1842-7. https://doi.org/10.1016/j.jpedsurg.2016.12.009

10. Shah M, Odugoudar A, Chawla A, Hameed ZB. Transverse testicular ectopia: two rare adult cases and a review of literature. BMJ Case Reports CP. 2020 May 1;13(5):e232240. https://doi.org/10.1136/bcr-2019-232240

11. Muraveji Q, Sherzad A. Transverse Testicular Ectopia. Journal of Pediatric Surgery Case Reports. 2020 Dec 1;63:101694 https://doi.org/10.1016/j.epsc.2020.101694

## Disclaimer and Publisher's Note

The statements, opinions and data contained in all publications are solely those of the individual author(s) and contributor(s) and not of Swiss J. Radiol. Nucl. Med. and/or the editor(s). Swiss J. Radiol. Nucl. Med. and/or the editor(s) disclaim responsibility for any injury to people or property resulting from any ideas, methods, instructions or products referred to in the content.

## License Policy

This work is licensed under a Creative Commons Attribution 4.0 International License: https://creativecommons.org/licenses/by/4.0/ . This license requires that reusers give credit to the creator. It allows reusers to distribute, remix, adapt, and build upon the material in any medium or format, even for commercial purposes.

## SJORANM LinkedIn

Journal profile: https://www.linkedin.com/in/sjoranm-swiss-j-radiol-nucl-med-4b00b427a/